

**Original Article**

# COMPARISON OF CLINICAL EFFECTIVENESS OF HYDROCHLORIC ACID AND SODIUM HYPOCHLORITE IN MICROABRASION TECHNIQUE FOR THE TREATMENT OF DENTAL FLUOROSIS: A RANDOMIZED CONTROL TRIAL

Hareem Abdul Sattar<sup>1</sup>, Muhammad Ali Sheikh<sup>2</sup>, Baneen Abdul Sattar<sup>3</sup>

<sup>1</sup>Department of Operative Dentistry and Endodontics, Shahida Islam Dental College, Lodhran, Punjab

<sup>2</sup>Department of Prosthodontics, Baqai Medical University, Karachi

<sup>3</sup>Department of Research, Dow University of Health Sciences, Karachi

## ABSTRACT

**Objectives:** The aim of this study is to compare the clinical effectiveness of hydrochloric acid-pumice compound and sodium hypochlorite-pumice compound in treating dental fluorosis using micro abrasion technique.

**Materials and Methods:** A Randomized Clinical Trial were carried out in Fatima Jinnah Dental College & Hospital, Karachi, from 1st November 2019 to 30th April 2020. Total 30 patients in each group were included. Preoperatively shade was checked. The mixture was applied 10 times or more during the same session. Total treatment time was around 30 minutes. Every patient received entire micro abrasion treatment. At the end of the treatment, neutral sodium fluoride gel was applied. Then changes in shade were checked. Descriptive statistics were calculated. Chi square test was applied to compare effectiveness of both groups. P-value <0.05 as significant.

**Results:** There were 53.3% male and 46.7% female patients in Group-A (hydrochloric acid-pumice compound) and 60% male and 40% female patients in Group-B (sodium hypochlorite-pumice compound). Mean pre-operative shade in group-A and group-B was  $4.53 \pm 0.50$  and  $4.66 \pm 0.47$  respectively. Mean post-operative shade in group-A and group-B was  $2.90 \pm 0.75$  and  $3.96 \pm 0.99$  respectively. Effectiveness was found 90% in group-A and 53.3% in group-B. The results showed significant association of effectiveness with study groups.

**Conclusion:** Effectiveness was 90% with hydrochloric acid-pumice compound and 53.3% with sodium hypochlorite-pumice compound. The enamel micro abrasion is efficient and effective for producing esthetic improvements.

**Key words:** Hydrochloric Acid, Sodium Hypochlorite, Dental Fluorosis, Micro abrasion Technique.

**Cite as:** Sattar HA, Sheikh MA, Sattar BA. Comparison of clinical effectiveness of hydrochloric acid and sodium hypochlorite in microabrasion technique for the treatment of dental fluorosis: a randomized control trial. Journal of Khyber College of Dentistry Jun 2025, Vol. 15, No. 2. <http://doi.org/10.33279/jkcd.v15i02.72>

## INTRODUCTION

Donly et al<sup>7</sup> demonstrated that a dense, prismatic layer forms on the surface of abraded enamel, giving

### Correspondence:

**Dr. Hareem Abdul Sattar**

Assistant Professor

Department of Operative Dentistry and Endodontics, Shahida Islam Dental College, Lodhran, Punjab

Email: hareemgaziani@gmail.com

Date Submitted: June 2024

Date Revised: August 2024

Date Accepted: November 2024

the tooth a glass-like sheen. The optical features of the freshly micro-abraded surface mask the residual subsurface stains. This property of vitreous materials is known as the "abrasion effect" or "enamel glaze." This aspect was validated by the clinical appearance and microscopically corroborated by the presence of smooth and regular microabraded enamel<sup>7</sup>. Croll used the phrases "fluorosis-type stains" and "fluorosis-like demineralization" in 1998<sup>11</sup> to characterise the chromatic changes in the enamel surface caused

by a disruption in the mineralization process. It has been documented 9, 11, and 12 that the texture of the intrinsic white stain (i.e., a stain of hard texture and any colour presented on the buccal surface of the anterior and premolar teeth) is the primary indicator for the microabrasive operation, rather than its aetiology. The microabrasion procedure to remove enamel stains causes minimal loss of enamel when related to the total amount of remaining enamel<sup>13</sup> and clinically over time, promotes the achievement of an enamel surface with considerable uniformity, smoothness, and luster, which is known as the “abrosion effect”. This, according to Croll in 1991<sup>11</sup> Donly and others in 1992<sup>7</sup> and Segura in 1993<sup>12</sup> is the result of the deposition of mineral substances from the abrasive and erosive action of the microabrasive compound.

Dental fluorosis is a condition in which the enamel becomes hypomineralized as a result of excessive fluoride consumption, resulting in opaque white regions or discolorations ranging from yellow to dark brown, as well as porosities on the enamel surface<sup>1</sup>. Fluorosis staining is widely regarded as an aesthetic issue due to the psychological impact of unsightly maxillary or mandibular anterior teeth<sup>2</sup>. Dental fluorosis, on the other hand, is not the only cause of enamel demineralization. Some perturbations in the mineralization process may cause opaque white to golden brown discolorations, even with pitting<sup>3</sup>. Their distinction can be made based on their locations, since stains caused by dental fluorosis are commonly found on all teeth mineralizing at the same time, and fluorosis stains are likewise defined as non-discrete opaque enamel conditions<sup>4</sup>. Fluorosis stains are often treated in three ways: removing the stained enamel, whitening the affected tooth, and/or covering the stained area<sup>5</sup>. Enamel micro abrasion, vital bleaching, a combination of both procedures, and direct or indirect restorations for treating fluorosed teeth have all been documented in the literature as being compatible with these principles<sup>6</sup>. Options for treating unattractive discolouration of anterior teeth that compromise smile aesthetics include tooth preparation and invasive procedures such as porcelain veneers or bonded composite resin. As a result, a conservative strategy (e.g., micro abrasion) has been developed to remove stains and superficial dental abnormalities while preserving tooth structure and improving dental aesthetics<sup>7</sup>. Wright<sup>19</sup> suggested the etch-bleach-seal procedure for removing yel-

low-brown stains. First, the damaged tooth should be etched for 60 seconds with 37% phosphoric acid, followed by 5-10 minutes of continuous application of 5% sodium hypochlorite as the bleaching agent. The tooth must then be re-etched and coated with a protective covering, such as a clear fissure sealer or composite bonding agent<sup>20</sup>. In this investigation, only 53.3% of the mixture of sodium hypochlorite and pumice to remove dark stains was clinically effective. Enamel micro abrasion is a gentle way to remove surface enamel and correct discolorations. Depending on the number of applications and acid concentration, the enamel micro abrasion process results in a loss of enamel of 20-200 micrometres. The enamel micro abrasion process combines pumice or silica carbide particles with 18% hydrochloric acid or 37% phosphoric acid gel<sup>8</sup>. The purpose of this study is to compare the ability of the aforementioned chemicals to eliminate fluorosis stains. In Pakistan, no clinical investigation comparing the therapeutic efficiency of hydrochloric acid and sodium hypochlorite use in micro abrasion technique has been undertaken. Drinking and dietary habits influence the outcome of micro abrasion by affecting the severity and persistence of fluorosis stains, which can impact the effectiveness of treatment materials like hydrochloric acid and sodium hypochlorite. Our population's dietary and drinking habits differ from those of other populations. As a result, outcomes may differ from published data, and this provided me with a compelling reason to undertake this study in our local population. As a result, this research will assist us in determining the best and most appropriate material for micro abrasion technique in terms of clinical effectiveness.

## MATERIALS AND METHODS

The study was a randomised controlled experiment that looked at the clinical efficacy of hydrochloric acid and sodium hypochlorite used in the micro abrasion technique for treating dental fluorosis. The research was carried out at the Fatima Jinnah Dental College & Hospital's Department of Operative Dentistry in Karachi, Pakistan. The study received ethical approval from the institution's Ethical Committee and Review Board. Fluorosis patients were checked by a single calibrated operator. The experiment ran from November 1st, 2019, through April 30th, 2020. Researchers used the WHO calculator to determine the sample size, applying statistics of 94% for sodium

hypochlorite 21 and 12.1% for hydrochloric acid 14, with a test power of 90%. Although the calculated sample size was 60, the researchers only used 30 patients in each group.

The study included patients aged between 18 and 40 years who had permanent dentition, as confirmed through clinical examination. Eligible participants were required to have at least four maxillary incisors with a score of 4 on Dean’s Fluorosis Index and no caries or restorations on the teeth to be treated. Patients were excluded if they exhibited poor oral or general health, had a history of smoking or tobacco use, showed signs of periodontal disease, had caries on anterior teeth, or experienced hypersensitivity in the teeth, all assessed through clinical examination. The teeth were initially cleaned with preventive paste so that they could be appropriately evaluated. The teeth were then dried using cotton rollers, and the degree of discoloration was evaluated 30 seconds after air drying. The Dean's Fluorosis Index 24 was used to determine the severity of fluorosis on maxillary and mandibular incisors and canines. Patients with moderate fluorosis, as measured by Dean's Fluorosis Index, were taken in the study. In this clinical trial, a total of 60 patients were enrolled, with 30 participants in each of two groups. With the use of the VITA traditional A1-D4® shade guide, the initial tooth colour was recorded. The order of the VITA classical family of hues is as follows: A1 - A4 (reddish brownish), B1 - B4 (reddish-yellowish), C1 - C4 (greyish tones), and D2 - D4 (dark brownish) (reddish-grey). The shade of teeth was evaluated in natural daylight. The closest color was chosen from the shade tab. A single calibrated operator administered micro abrasion treatment. A lottery was used to select one of the aforementioned materials. Before beginning treatment, a rubber dam was used to isolate the anterior teeth. On top of the fluorosis stains, a 1 mm thick layer of slurry comprised of any of the aforementioned substances (18% HCl and 5% sodium hypochlorite) mixed with pumice was applied. These surfaces were micro-abraded for 30 seconds utilizing rubber prophylaxis cups linked to a slow-speed handpiece and a light amount of pressure. Following each treatment, the teeth were rinsed with water spray. Ten or more applications of the mixture were made during the same session. The duration of treatment was roughly 30 minutes. Every patient was treated with micro abrasion in a single consultation.

Four minutes were spent applying neutral sodium fluoride gel (1,2%) at the conclusion of the procedure. The post-operative alteration in tooth shade was then evaluated using the VITA traditional A1-D4® shade guide. Effectiveness was deemed positive if there was at least one shift in shade from baseline to shade group A1-D4 immediately after the procedure. If there is no change in hue from the baseline, the effectiveness was deemed negative.

The data were analysed using version 21 of SPSS. Due to the quantitative nature of the data, the mean and standard deviation were determined for age. Frequency and percentage were computed for gender and efficacy (measured by change in tooth shade using the VITA traditional A1-D4® shade guide). The effectiveness of the two groups were compared using the chi-square test. Effect modifiers such as age and gender were managed using stratification. A post-stratification chi-square test was conducted with a significance threshold of P 0.05.

## RESULT

The purpose of this study was to assess the clinical efficacy of hydrochloric acid-pumice compound and sodium hypochlorite-pumice compound in treating dental fluorosis utilising micro abrasion. Thirty patients were involved in both experimental groups, Group A (hydrochloric acid-pumice compound) and Group B (sodium hypochlorite-pumice compound). The qualitative characteristics are presented as frequencies and percentages. The average and standard deviations of quantitative variables were reported. The purpose of stratification was to determine the impact of modifiable factors on outcome. The post-stratification chi-square test was done with significance set at P 0.05. As shown in Table-1, group A comprised 53.3% male and 46.7% female patients, whereas group B comprised 60% male and 40% female patients. Patients in group A and group B had mean ages of 25.234.08 and 25.434.44 years, respectively. Table 2 presents the descriptive statistics for age. Age was further categorised into two

Table 1: Frequency distribution of gender

	MALE (%)	FEMALE (%)	TOTAL
GROUP A	16 (53.3 %)	14 (46.7 %)	30
GROUP B	18 (60 %)	12 (40 %)	30

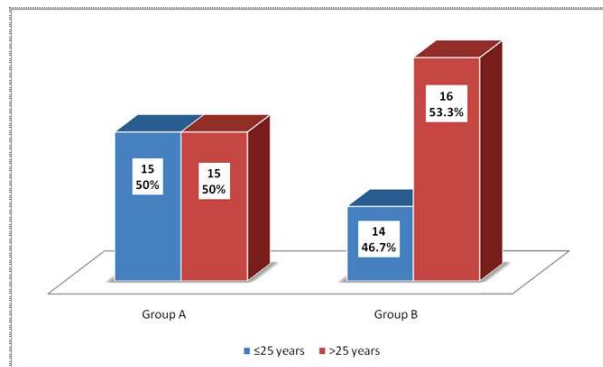
\*A (Hydrochloric Acid – Pumice Compound)\*\* B (Sodium Hypochlorite-Pumice Compound)

groups. In Figure-2, the frequency and percentage of age groups are displayed. Table-3 displays that the mean pre-operative tooth shade for groups A and B was 4.530.50 and 4.660.44 correspondingly. In Table-4, the mean post-operative tooth shade for groups A and B was 2.900.75 and 3.960.99, respectively. In our study, 90% of cases in group A and 53.3% of cases in group B were effective, as shown in Table 5. The effectiveness of the two groups were compared using the chi-square test. P values 0.05 were deemed significant. As shown in Table 6, the results revealed a significant connection between study groups and effectiveness (p=0.002).

**DISCUSSION**

It is frequently difficult to assess the real depth of intrinsic enamel stains. Since it is a less intrusive and more conservative operation, enamel microabrasion should be the initial treatment choice. This treatment

has the advantages of requiring less structural removal, eliminating sensitivity and post-operative pain, requiring no tooth preparation, requiring less time, and being simple to execute. 9, 10 Microabrasion conceals, eliminates discoloured tooth structure, and improves tooth colour. During processing, a highly polished, densely packed mineralized structure forms the surface layer. This method combines



**Fig 2: Frequency and percentage of patients according to age group (n=60)**

**Table 5: Frequency distribution of effectiveness for Group A and Group B**

	n (%) Yes	n (%) No	Total
Group A	27 (90 %)	3 (10 %)	30
Group B	16 (53.3 %)	14 (46.7 %)	30

**Table 6: Frequency of effectiveness according to study group (n=60)**

Effectiveness	Study Group		Total	P-Value
	Group A	Group B		
Yes	27 (62.8)	16 (37.2)	43	0.002*
No	3 (17.6)	14 (82.4)	17	
Total	30	30	60	

Score	Criteria	Definition
0	Normal	Smooth, bright, pale creamy-white translucent surface. No white discoloration of teeth.
1	Questionable	A few white flecks or white spots mainly on the edge of the incisors and cuspids.
2	Very mild	Small opaque white areas covering less than 25% of the tooth surface.
3	Mild	Opaque white areas covering less than 50% of the tooth surface.
4	Moderate	All tooth surfaces are affected; a marked deterioration of occlusal surfaces; brown stains may be present.
5	Severe	All tooth surfaces are affected; discrete or confluent holes; brown stains present.

**Fig 1: Dean’s fluorosis index<sup>24</sup>**

**Table 2: Descriptive statistics of age (years) for Group A and Group B**

	Mean	Standard Deviation	Median	Minimum	Maximum	Range
Group A	25.23	4.08	26.00	18	31	13
Group B	25.43	4.46	26.50	18	32	14

**Table 3: Descriptive statistics of pre-operative tooth shade for Group A and Group B**

	Mean	Standard Deviation	Median	Minimum	Maximum	Range
Group A	4.53	0.50	5.00	4	5	1
Group B	4.66	0.47	5.00	4	5	1

**Table 4: Descriptive statistics of post-operative tooth shade for Group A and Group B**

	Mean	Standard Deviation	Median	Minimum	Maximum	Range
Group A	2.90	0.75	3.00	2	5	3
Group B	3.96	0.99	3.50	3	5	2

hydrochloric acid or phosphoric acid with abrasive powder to remove the enamel's surface layer.<sup>10</sup> A study was conducted by Celik et al.<sup>14</sup> which aimed at evaluating the effect of severity of fluorosis on the clinical performance of enamel microabrasion using 6.6% hydrochloric acid (HCL). It was reported that an improvement was observed in 63.5% patients with mild fluorosis and 12.1% with severe fluorosis. The present study reported that in the group which was treated with hydrochloric acid (HCL) for the purpose of enamel microabrasion, improvement was observed in 90% of the patients reported satisfaction with the treatment. Another study conducted by Sheoran et al.<sup>15</sup> aimed to compare the clinical efficacy of enamel microabrasion using 18% hydrochloric acid and 37% phosphoric acid on removal of visually unaesthetic developmental enamel defects of young permanent anterior teeth in children. It was reported that group treated with HCL had 81.4% while phosphoric acid was found efficacious in 81.7% of the patients. Gupta et al.<sup>16</sup> conducted a study which aimed at evaluating the effectiveness of the different treatment modalities for the removal of unaesthetic dental fluorosis stains in children.<sup>16</sup> According to the treatment options, the patients were separated into three groups: in-office bleaching with 35% hydrogen peroxide (Group 1), enamel microabrasion followed by in-office bleaching with 44% carbamide peroxide gel (Group 2), and in-office bleaching with 5% sodium hypochlorite (Group 3). The author found that 90% of Group 1 patients were pleased with their appearance immediately following therapy. 83% of Group 2 patients were pleased with their appearance immediately following therapy. 73% of Group 3 patients were pleased with their appearance immediately following therapy. 53.3 percent of patients treated with sodium hypochlorite at a concentration of 5.25 percent indicated clinical effectiveness. Hansija et al.<sup>17</sup> conducted a clinical trial including 18% hydrochloric acid and 37% phosphoric acid for the removal of fluorosis stains. Both substances were exceptionally effective in removing stains, but hydrochloric acid required fewer treatments and so caused less enamel damage. The present investigation also demonstrates that hydrochloric acid yields superior results. Nevárez-Rascón M et al.<sup>18</sup> The microabrasion approach employing 16% HCL was effective in 90.6% of patients and was manually applied to superficial fluorosis stains. Aurora et al.<sup>22</sup> tested the clinical effectiveness of a 5% sodium hypochlorite

solution for removing fluorosis stains from the teeth of young patients. This approach appears to have benefits for enhancing the appearance of fluorosis stains. It is a straightforward, inexpensive, and non-invasive method. As mentioned by Wright<sup>19</sup>, the author utilised sodium hypochlorite as a bleaching agent to remove yellow-brown fluorosis stains. However, in our work, researchers combined sodium hypochlorite with pumice to remove fluorosis stains using the enamel microabrasion technique. Narendra et al.<sup>23</sup> bleached fluorotic stains with 5% sodium hypochlorite. Fluorosis stains have been clinically removed successfully using the method given in this case report.

This study is limited by the small sample size, hence additional structured investigations with larger samples are required. This study was conducted in an urban setting; therefore the results may not apply to bigger populations; this is another problem.

## CONCLUSION

In conclusion, this randomized controlled study demonstrated that the effectiveness was 90% with hydrochloric acid-pumice compound and 53.3% with sodium hypochlorite-pumice compound. Accumulating evidence suggested that enamel microabrasion is efficient and effective for producing esthetic improvements. This technique involves minimal enamel loss, leaving a smooth and shiny enamel surface with permanent results. The procedure is considered a safe, conservative, atraumatic method for removing superficial enamel stains and defects.

## REFERENCES

1. Saldarriaga A, Rojas-Gualdrón DF, Restrepo M, Bussaneli DG, Fragelli C, de Cássia Loiola Cordeiro R, Santos-Pinto L, Jeremias F. Clinical changes in the severity of dental fluorosis: a longitudinal evaluation. *BMC Oral Health*. 2021 Dec;21:1-9.
2. Sujak SL, Kadir RA, Dom TN. Esthetic perception and psychosocial impact of developmental enamel defects among Malaysian adolescents. *Journal of Oral Science*. 2004;46(4):221-6.
3. Cavalheiro JP, Giroto Bussaneli D, Restrepo M, Bullio Fragelli CM, Loiola Cordeiro RD, Escobar Rojas A, Santos-Pinto L, Jeremias F. Clinical aspects of dental fluorosis according to histological features: a Thylstrup Fejerskov Index review. *CES Odontologia*. 2017 Jun;30(1):41-50.
4. Bhagavatula P, Levy SM, Broffitt B, Weber-Gasparoni K, Warren JJ. Timing of fluoride intake and dental flu-

- orosis on late-erupting permanent teeth. *Community dentistry and oral epidemiology*. 2016 Feb;44(1):32-45.
5. Lee JD, Inoue N, Lee C, Park S, Lee SJ. Comprehensive management of severe dental fluorosis with adhesively bonded all-ceramic restorations. *Prosthesis*. 2021 Jul 26;3(3):194-208.
  6. Shahroom NS, Mani G, Ramakrishnan M. Interventions in management of dental fluorosis, an endemic disease: A systematic review. *Journal of family medicine and primary care*. 2019 Oct 31;8(10):3108-13.
  7. Donly KJ, O'Neill M, Croll TP. Enamel microabrasion: a microscopic evaluation of the "abrosion effect". *Quintessence international*. 1992 Mar 1;23(3).
  8. Bagda K, Patel Z, Mansuri R, Attur K, Vachhani K, Patel P. DENTAL FLUOROSIS THE MICROABRASION WAY OF MANAGEMENT -CASE REPORTS. *International Journal of Advanced Research*. 2020;8(6):942-945.
  9. Wang Y, Sa Y, Liang S, Jiang T. Minimally invasive treatment for esthetic management of severe dental fluorosis: a case report. *Operative dentistry*. 2013 Jun 1;38(4):358-62.
  10. Sundfeld D, Pavani CC, Pini NI, Machado LS, Schott TC, Sundfeld RH. Enamel microabrasion and dental bleaching on teeth presenting severe-pitted enamel fluorosis: A case report. *Operative dentistry*. 2019 Nov 1;44(6):566-73.
  11. Croll TP, Helpin ML. Enamel microabrasion: a new approach. *Journal of Esthetic and Restorative Dentistry*. 2000 Mar;12(2):64-71.
  12. Segura A, Donly KJ, Wefel JS. The effects of microabrasion on demineralization inhibition of enamel surfaces. *Quintessence International*. 1997 Jul 1;28(7).
  13. Sundfeld RH, Croll TP, Briso AL, De Alexandre RS. Considerations about enamel microabrasion after 18 years. *American journal of dentistry*. 2007 Apr 1;20(2):67-72.
  14. Celik EU, Yildiz G, Yazkan B. Clinical evaluation of enamel microabrasion for the aesthetic management of mild-to-severe dental fluorosis. *Journal of Esthetic and Restorative Dentistry*. 2013 Dec;25(6):422-30.
  15. Sheoran N, Garg S, Damle SG, Dhindsa A, Opal S, Gupta S. Esthetic management of developmental enamel opacities in young permanent maxillary incisors with two microabrasion techniques—a split mouth study. *Journal of Esthetic and Restorative Dentistry*. 2014 Sep;26(5):345-52.
  16. Gupta A, Dhingra R, Chaudhuri P, Gupta A. A comparison of various minimally invasive techniques for the removal of dental fluorosis stains in children. *Journal of Indian society of pedodontics and preventive dentistry*. 2017 Jul 1;35(3):260-8.
  17. Kumar D, Singh A, Mukherjee CG, Ahmed A, Singh A, Hasija MK, Anand S. Clinical efficacy of hydrochloric acid and phosphoric acid in microabrasion technique for the treatment of different severities of dental fluorosis: An: in vivo: comparison. *Endodontology*. 2019 Jan 1;31(1):34-9.
  18. Nevárez-Rascón M, Molina-Frechero N, Adame E, Almeida E, Soto-Barreras U, Gaona E, Nevárez-Rascón A. Effectiveness of a microabrasion technique using 16% HCL with manual application on fluorotic teeth: A series of studies. *World journal of clinical cases*. 2020 Feb 2;8(4):743.
  19. Wright JT. The etch-bleach-seal technique for managing stained enamel defects in young permanent incisors. *Pediatr Dent*. 2002 May 1;24(3):249-52.
  20. Almuallem Z, Busuttil-Naudi A. Molar incisor hypomineralisation (MIH)—an overview. *British dental journal*. 2018 Oct;225(7):601-9.
  21. Sailema C, Wilfrido Á. Comparative study of the clinical efficacy of the technique of microabrasion combined with sodium hypochlorite 5% or of 35% hydrogen peroxide, to reduce dental chromatic alterations due to fluorosis in students Education Unit Intercultural Bilingual Manzanapamba parish Salasaca, canton Pelileo, Tungurahua provinc. [online] 2014
  22. Flores AC, Reyes HF, Moscoso AG, Castanedo Cázares JP, Pozos Guillén AD. Clinical efficacy of 5% sodium hypochlorite for removal of stains caused by dental fluorosis. *Journal of clinical pediatric dentistry*. 2009 Apr 1;33(3):187-92.
  23. Penumatsa NV, Sharanasha RB. Bleaching of fluorosis stains using sodium hypochlorite. *Journal of Pharmacy and Bioallied Sciences*. 2015 Aug 1;7(Suppl 2):S766-8.
  24. View Image [Internet]. *Ijdr.in*. [cited 2022 May 26]. Available from: URL:[https://www.ijdr.in/viewimage.asp?img=IndianJDentRes\\_2019\\_30\\_3\\_462\\_264119\\_t1.jpg](https://www.ijdr.in/viewimage.asp?img=IndianJDentRes_2019_30_3_462_264119_t1.jpg)

CONFLICT OF INTEREST  
Authors declare no conflict of interest.  
GRANT SUPPORT AND FINANCIAL DISCLOSURE  
None declared.

#### AUTHORS' CONTRIBUTION

The following authors have made substantial contributions to the manuscript as under:

Conception or Design: HAS, MAS, BAS

Acquisition, Analysis or Interpretation of Data: HAS, MAS, BAS

Manuscript Writing & Approval: HAS, MAS, BAS

All the authors agree to be accountable for all aspects of the work in ensuring that questions related to the accuracy or integrity of any part of the work are appropriately investigated and resolved.



This is an Open Access article distributed under the terms of the Creative Commons Attribution-NonCommercial 4.0 International License, which permits unrestricted use, distribution & reproduction in any medium provided that original work is cited properly.