

COMPARISON OF TWO TYPES OF DELTOPECTORAL FLAP FOR THE RECONSTRUCTION OF LOWER FACIAL DEFECTS

*Jawad Ahmad Kundi, *Shahid Khan Khattak, **Riaz Ahmed Warraich

* Sardar Begum Dental College, Gandhara University, Peshawar.

** Department of Oral & Maxillofacial Surgery, King Edward Medical University/ Mayo Hospital, Lahore.

ABSTRACT

Objective: To compare different variables between two surgical types of the delto-pectoral flap thereby reaching a consensus on the better flap among the two types.

Material and Methods: A total of 60 patients were included in this study who reported to the Department of Oral and Maxillofacial Surgery at King Edward Medical University, Lahore from March, 2005 to February, 2006 (one year) and who required lower facial reconstruction owing to previous facial trauma or following ablative tumour resection. These patients were randomly divided into two groups. Group A underwent reconstruction using a single-stage procedure involving de-epithelization and tunneling under the neck skin. Group B underwent the reconstruction of the defect using the conventional two-stage procedure in which defect was reconstructed with the flap and three weeks later the pedicle of the flap was transected and brought back to original donor site.

Results: Among group A patients, successful flaps were noticed in 83.3% of cases. Among group B 93.3% were successful were refused flaps were noticed in 73.3% of cases in both group A, and B following blanching test. Edge necrosis was seen in 40% patients in group A, while 33.3% in group B.

Conclusion: The two-stage flap technique should be employed as a norm in the lower face reconstruction owing to the significantly higher flap failure rate in the single-stage entity attributable probably to traction on flap pedicles during de-epithelization. Further studies are encouraged.

Key words: Deltopectoral flap, Lower face reconstruction, Reconstruction

INTRODUCTION

The deltopectoral (DP) flap remains a useful, reliable, and versatile regional flap that can be used alone or in combination with other flaps in selected circumstances for major head and neck reconstruction¹. The Deltopectoral flap has been described for resurfacing of cervical skin defects, for reconstruction after tracheostomal resection, to restore symmetry in unilateral neck dissections and to provide safe coverage to the carotid artery². It is commonly used to reconstruct defects resulting from ablative head and neck cancer surgery³ and is valuable in the reconstructive surgery of full-thickness defects of the cheek⁴. It is

rapidly harvested, reliable and adaptable to various reconstructive needs⁵. Expanded deltopectoral flap is very suitable for large size of cervical cicatricial contracture⁶. However, like all other surgical procedures, it has its fair share of disadvantages. Its limited arc of rotation and its tendency to be pulled down by the effects of gravity while tubed to the chest count are two of its major disadvantages⁷.

METHODOLOGY

This comparative interventional (quasi experimental) study was carried out at the Department of Oral and Maxillofacial Surgery, King Edward Medical University/Mayo Hospital, Lahore, Pakistan. The duration of the study was from March 2005 to February 2006.

A total of 60 patients were included in this study who needed reconstruction of tissue defects in

Correspondence:

Dr. Jawad Ahmad Kundi

Associate Prof. Department of Oral & Maxillofacial Surgery
Sardar Begum Dental College, Gandhara University, Peshawar
Cell: 0333-9126606

Email address: drjkundi@yahoo.com

the lower face owing to previous trauma or following ablative tumour resection. These were divided in two groups of 30 each; Group A was reconstructed with the single-stage procedure wherein the flap was raised, part of it was de-epithelized and then tunneled under a neck flap to be brought eventually to the recipient site. In group B, the DP flap was raised and brought directly to the recipient site without de-epithelization. After an interval of 3 weeks, the remainder of the flap was divided and brought back to the donor site and inset in its original position.

The flap color was compared at discharge and at 3 months follow-up, blanch test at discharge and at three months follow-up, edge necrosis at discharge and at three months follow-up and any donor site abnormalities at discharge and at three months follow-up. All these variables were compared for both the groups.

RESULTS

Distribution by flap color: At discharge from Hospital after the final surgery, the flap color was found normal for 20 patients (66.7%) in group A. In the remaining ten patients (33.3%) flap color was found to be in close proximity of cyanotic appearance.(Fig 1) At follow-up visits, it was noted that only 5 (16.7%) of the group A sample showed a cyanotic appearance . These were registered as failed flaps as necrosis of the flaps had ensued in the period before follow up. In group A 25 of the flaps (83.3%) were found to be successful with no signs of failure showing that 5 patients improved during the period of follow. (Fig 2)

In Group B, at final discharge from hospital, 27 patients (90%) showed normal appearance of their flaps while only 3 patients (10%) showed a cyanotic appearing flap. (Fig 1) Only 2 flaps (6.7%) showed signs of failure at follow up in Group B. 28 flaps (93.3%) showed no signs of failure and were normal at the follow up visit.(Fig 2)The P-value for flap colour among the two groups was found to be not significant (P > 0.05) .

Distribution by blanching test

Blanching test was used to assess the perfusion of the flap at the time of discharge of patient from the hospital. In Group A 22 patients (73.3%) showed a positive response showing a well-perfused flap while 8 patients (26.7%) showed a negative response to blanching test . (Fig 3) At follow-up, 5 flaps (16.7%) were deemed un-successful in group A.

Group B showed the exact results that group A showed at discharge. At follow-up, 2 flaps (6.7%) showed no response to the blanching test and were declared failed flaps(Fig 4).The P-value was found to be not significant at P > 0.05.

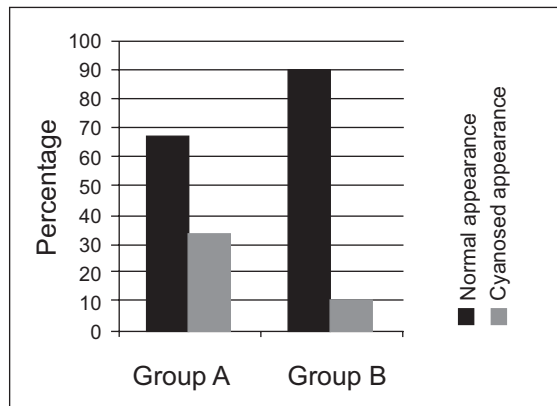


Fig - 1: Comparison of Flap colour at final discharge in both the groups. (n=30)

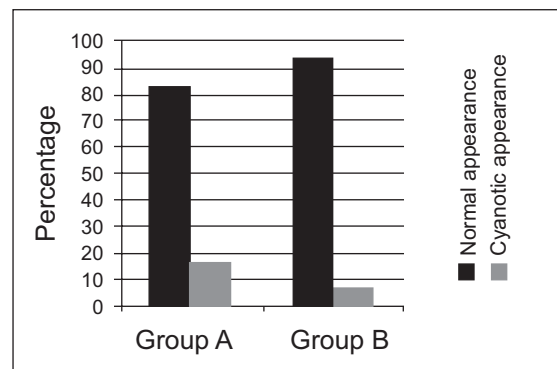


Fig - 2: Comparison of Flap colour at follow up for patients in both the Groups. (n=30)

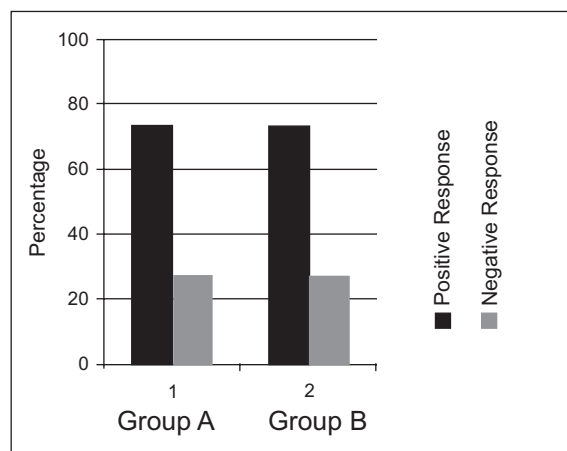


Fig - 3: Comparison of Blanching test response at final discharge in both the groups. (n=30)

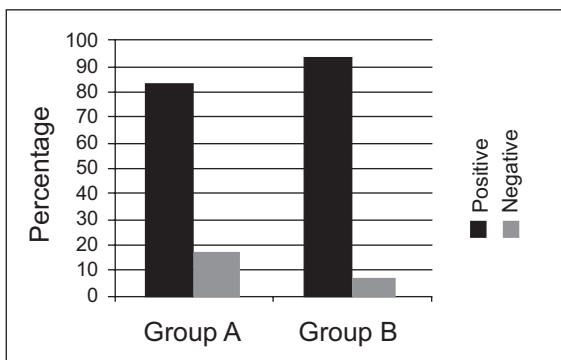


Fig - 4: Comparison of Blanching test for patients at follow-up in both the groups (n=30)

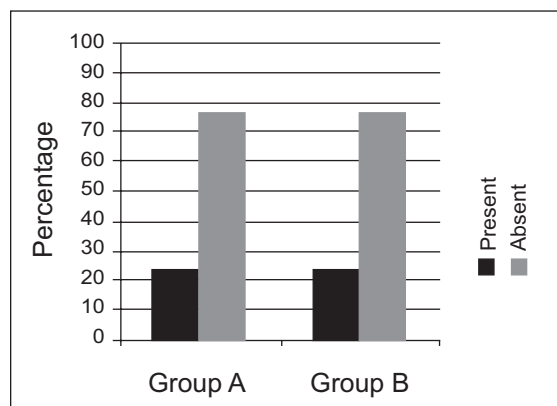


Fig - 7: Comparison of Donor site abnormalities at final discharge among both the groups (n=30)

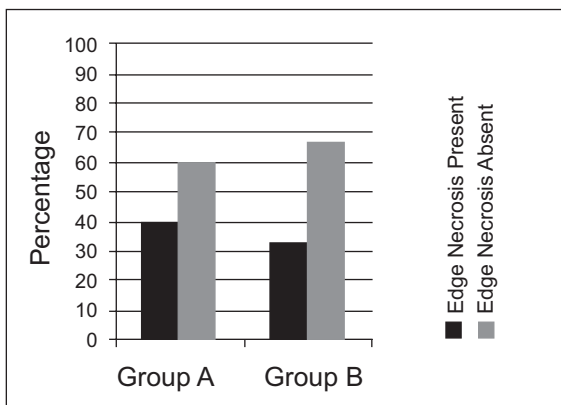


Fig - 5: Comparison of Edge necrosis at discharge in both the groups (n=30)

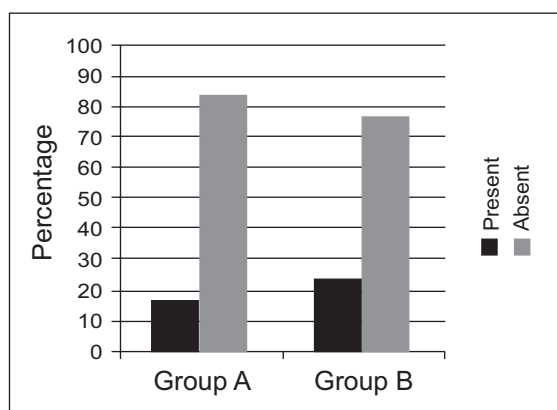


Fig - 8: Comparison of Donor site abnormality at follow up amongst the two groups (n=30)

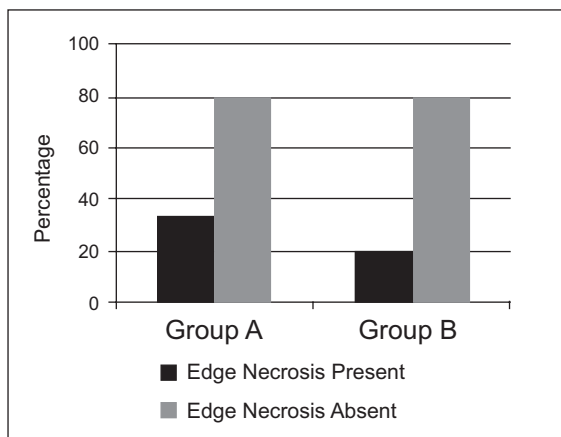


Fig - 6: Comparison of Edge necrosis at follow up among both the groups. (n=30)

Distribution by edge necrosis

Of the 30 flaps in group A, only 12 (40%) showed varying degrees of edge necrosis while 18 (60%) of the flaps did not show any signs of edge necrosis at final discharge from hospital. (Fig 5) At

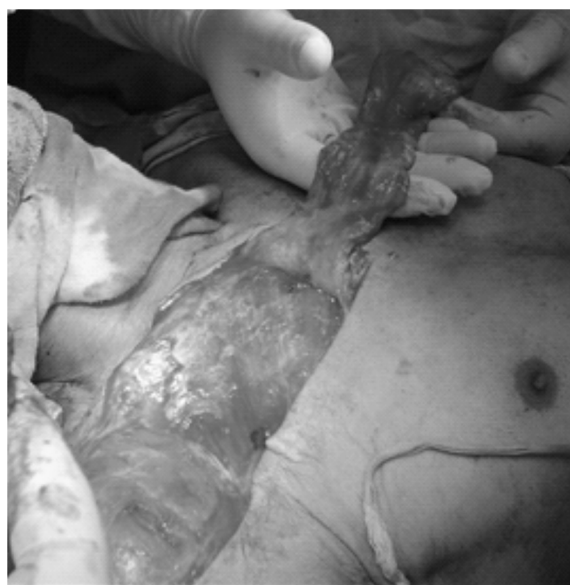

Fig - 9: A deltopectoral flap raised . This is going to be de-epithelialized and tunneled under the neck skin to reach an intra-oral site.

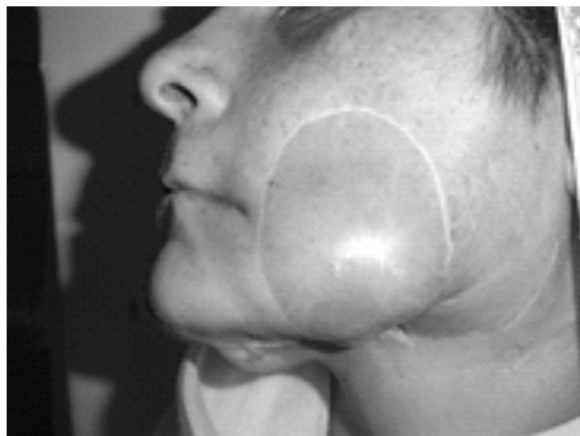

Fig - 10: A deltopectoral flap used for reconstruction of a Carcinoma of cheek defect. 3 months post op picture

follow-up, 10 patients (33.3%) showed varying degrees of edge necrosis at follow up. Of these, five cases also showed corroborative signs of flap failure and were declared unsuccessful. 20 cases in Group A (66.6%) did not show any signs of edge necrosis at follow up (Fig 6).

Only 10 patients (33.3%) showed signs of edge necrosis of varying degrees at final discharge from hospital in Group B. However, two-thirds of the patients (66.7%) showed no sign of edge necrosis at discharge from Hospital. (Fig 5) At follow-up, 24 cases (80%) did not show any signs of edge necrosis while only 6 cases (20%) showed some degree of edge necrosis. Of these 6 cases, showing signs of necrosis, 2 showed other corroborative signs of failure & were declared as failed flaps. The remaining 4 flaps' edges were de-brided and re-sutured resulting in good healing in all 4 cases (Fig 6). The P-value for this variable was found to be insignificant with $P > 0.05$.

DISCUSSION

The post-operative assessment of the flap condition was used as a subjective measure of the flap's success. At discharge, 67% flaps showed a normal color in Group A while 90% flaps were normal at the time of discharge in Group B. This is not a significant difference as $P > 0.05$. Both groups showed an identical percentage of a positive response to the blanching test, i.e. 73.3%. Group A had 40% cases showing some degree of edge necrosis while Group B had 33.3% of cases showing edge necrosis. The p-value for this variable was found to be more than 0.05 and was therefore not significant.

At follow up, Group A showed a remarkable improvement in flap color and 83.3% of the cases showed a normal flap color. Five flaps, however were completely lost and were declared failed. In group B only two flaps were declared failed with a normal flap color in 93.3% of the flaps in this group. The same percentage was true for both the groups again in Response to Blanching Test, with group A's all surviving flaps showing a positive response to the blanching test, i.e. 83.3% while group B's all surviving flaps following suit i.e., 93.3%.

Edge necrosis had improved in both the groups when compared to their respective times of discharge but Group B fared well as only in 20% of the cases edge necrosis was present. Group A showed edge necrosis of varying degree in 33.3%.

The flap failure rate of 17% in group A is comparable to other such reported case series in the literature. Ma⁸ and Cheema⁹ reported a flap failure rate of 16% and 15% respectively, are comparable to our study's group A.

The flaps used for Group B showed a failure rate of 7%. This is comparable with the results achieved by Vtiurin and Klim¹¹, who in their study reported a failure rate of 5% in the same type of flaps. Lejour et al¹² and Chan et al¹³ reported a much higher failure rate of 16%. Tiwari et al¹⁴ used the same flap but reported a failure rate of 13.6%. Kirkby et al¹⁰ reported a case series of 103 non-delayed Deltopectoral flaps in 86 patients. Their flap failure rate was in the range of 10%-20%. They also argued that this failure rate may increase to 50% in cases of intra-oral reconstructions. However 100% success rate has also been documented in the literature^{15,16}. The patients in Group B when compared to precedents in literature, did better than most of the articles presented in the past. However, exceptions are there. Kingdom and Singer^{14,16} in 1996 presented as case series of 24 patients and reported a 100% success rate.

The higher flap failure rate in Group A can be attributed to many causes including the usual post-operative complications of suture dehiscence, kinking of the pedicle of the flap, pressure on the pedicle of the flap and traction on the pedicle^{9,10,17,18}. However, it is interesting to note that essentially all the same factors that posed a threat to the Type A flap also posed a threat to the Type B flap as both flaps were located in identical environments. However, one step in type

A flap pre-disposes it more to failure than the type B flap: the de-epithelialization of the flap. This can place the nubile vascular supply of the flap skin under considerable danger, eventually starting the vicious circle of skin necrosis, infection and eventually the loss of the whole flap.

CONCLUSION

From this study the following conclusion is drawn:

- The single-stage procedure involving de-epithelialization of the flap, albeit more economical, both time-wise and financially, doesn't give as good a result with regards to flap survival as the two-stage procedure. Hence this procedure should only be performed where there is a specific indication for it, i.e. intra-oral reconstructions.
- De-epithelialization of the flap should be undertaken by experienced hands.
- The two-stage procedure, involving a subsequent division, should be employed as a norm in the lower face reconstruction owing to its higher flap success rate.

RECOMMENDATION

Further studies are encouraged to reach a consensus view about the type of flap most suited to lower face soft tissue reconstruction.

REFERENCES

1. Aymard J L. Nasal reconstruction. With a note on nature's plastic surgery. *Lancet*.1917;2:888-91.
2. Bakamjian VY. A two-stage method for pharyngoesophageal reconstruction with a primary pectoral skin flap. *Plast Reconstr Surg*. 1965;36:173-84.
3. Quereshy F A, Powers M P. Reconstruction of the maxillofacial cancer patient. In: Fonseca RJ, Powers MP, Barber HD. *Oral and Maxillofacial Surgery: Reconstructive and Implant Surgery*. 1st ed. Philadelphia: W B Saunder Company 2000; 361-444.
4. Gilas T, Sako K, Razack MS, Bakamjian VY, Shedd DP, Calamel PM. Major head and neck reconstruction using the deltopectoral flap: A 20 year experience. *Am J Surg* 1986;152:430-4.
5. Sharma PP, Jamkar AV. Use of Island deltopectoral flap in reconstructive head neck oncology. *Indian J Cancer*

- 2000 ; 37:105-10.
6. Mogi G, Fujiyoshi T, Kurono Y, Kawauchi H, Yoshimura H. Reconstructive surgery of head and neck cancer using various pedicle flaps. *Auris Nasus Larynx* 1985;12 (Suppl 2):S24-9.
7. Ord R A, Blanchaert Jr R H. Local and regional flap reconstruction of maxillofacial defects. In : Booth P W, Schendel S A, Hausamen J E. *Maxillofacial surgery*.1st ed. London: Churchill Livingstone 1999; 617-638.
8. Ma XJ, Peng P, Zheng Y, Guo SZ, Han Y, Lu KH. Expanded deltopectoral flaps for treatment of cervical cicatricial contracture. *Zhonghua Zheng Xing Wai Ke Za Zhi*. 2010 Jan;26(1):21-3
9. Cheema SA. Experience with deltopectoral flap. *Ann K E Med Coll* 2003;9:43-5.
10. Kirkby B, Krag C, Siemssen OJ. Experience with the deltopectoral flap. *Scand J Plast Reconstr Surg*. 1980;14:151-157.
11. Vtiurin BM, Klim KI. Primary plastic surgery of skin defects with delto-pectoral flap after resection of disseminated neck tumors. *Vestn Khir Im I I Grek* 1976; 116: 78-82.
12. Lejour M, Dor P, Jortay A, Mendes da Costa P, el-Hafed A. Experience with 38 deltopectoral flaps in reconstructive surgery of the head and neck. *Acta Chir Belg* 1977;76:179-84.
13. Chan RCL, Chan JYW. Deltopectoral Flap in the Era of Microsurgery. *Surgery Research and Practice* Volume 2014 (2014), <http://dx.doi.org/10.1155/2014/420892>.
14. Tiwari RM, Gorter H, Snow GB. Experiences with the deltopectoral flap in reconstructive surgery of the head and neck. *Head Neck*. 1981;3:379-383.
15. Kingdom TT, Singer MI. Enhanced reliability and renewed applications of the deltopectoral flap in head and neck reconstruction. *Laryngoscope* 1996;106:1230-3.
16. Schellekens PPA, Paes EC, Hage JJ, van der Wal MBA, Bleys RLW, Kon W. Anatomy of the vascular pedicle of the internal mammary artery perforator (IMAP) flap as applied for head and neck reconstruction. *Journal of Plastic, Reconstructive and Aesthetic Surgery* 2011; 64(1): 53-7.
17. Schmidt M, Aszmann OC, Beck H, Frey M. The anatomic basis of the internal mammary artery perforator flap: a cadaver study. *Journal of Plastic, Reconstructive and Aesthetic Surgery* 2010; 63(2): 191- 6.
18. Bakamjian VY, Poole M. Maxillo facial and palatal reconstructions with the deltopectoral flap. *British Journal of Plastic Surgery* 1977; 30(1): 17-37.