

## ANGIOKERATOMA OF THE TONGUE: A CASE REPORT

Atta-ur-Rehman, Bushra Mehboob, Fahim ud Din, Nadia Mansoor,

Department of Oral & Maxillofacial Surgery Khyber College of Dentistry, Peshawar.

### ABSTRACT

*Angiokeratoma is a skin disorder that rarely involves oral cavity. It can either occur in localized or generalized form, and is often associated with underlying metabolic disorder. In oral cavity, the most common site affected is tongue. We present a case of solitary Angiokeratoma of the tongue in a 10 years old female child. Pain and bleeding from the lesion was the presenting complaint of the patient. Excision of the lesion was carried out under general anesthesia*

**Key Words:** Angiokeratoma, Angiokeratoma of the tongue.

### INTRODUCTION

Angiokeratoma is a rare muco cutaneous disorder with a clear morphologic pattern. Several causative factors including congenital development, pregnancy, trauma, sub cutaneous hematomas, and tissue asphyxia have been reported in literature, however the exact pathogenesis remains unknown<sup>1</sup>. It has been postulated that local irritating factors may lead to acanthosis of epidermis<sup>2</sup>.

Clinically it occurs either as generalized or a localized lesion. Generalized form, called Angiokeratoma corporisdiffusum, is associated with an underlying metabolic disorder, like Fabry's disease and fucosidosis<sup>3</sup>. Solitary localized angiokeratoma without systemic involvement is a rare occurrence and few cases have been reported in literature<sup>4</sup>. Localized lesions may present in one of four forms,; (a) papular limited to the legs; (b) bilateral on the dorsum of toes and fingers (Mibelly type); (c) lesions limited to the scrotum or vulva (Fordyce type); and (d) a congenital form in which multiple lesions on the legs are usually found<sup>5</sup>.

Angiokeratoma can mimic a number of conditions like malignant melanoma, hemangioma, verruca vulgaris, basal cell carcinoma and pig-

mented nevus<sup>6</sup>. Diagnosis of angiokeratoma is often made on the basis of histopathology supported by clinical findings. Histologically angiokeratoma is characterized by hyperkeratosis and acanthosis of the epidermis<sup>7</sup>. Multiple keratotic plaques or papules are often present<sup>8</sup>. Surgical excision is carried out as definitive treatment. Laser ablation has also been proven to be effective. The prognosis of Angiokeratoma is good. Recurrence is rarely reported in literature<sup>9</sup>.

### CASE REPORT

A 10 year old female patient reported to Out Patient Department of Khyber College of Dentistry Peshawar, with two swellings on dorsum of tongue since 1 year (Figure-1). The swelling was associated with pain and bleeding. Clinically an exophytic, papillomatous, well demarcated mass of 2.5 cm was found on anterior dorsum of the tongue. Similar swelling of 2 cm size was present in mid dorsum. It was firm on palpation. Tender Lymphadenopathy of the submandibular lymph node was noted. There were no other lesions on the skin. Lymphangioma and hemangioma were considered in clinical differential diagnosis. Routine investigations for general anesthesia were normal. Excision of lesion was carried out and sent for histopathology report. The report revealed the diagnosis of Angiokeratoma with acanthosis, parakeratosis, elongation of rete ridges and congested thin walled dilated capillaries in papillary sub epithelial tissue with mix chronic inflammatory infiltrate composed of lymphocytes and plasma cells.

---

#### Correspondence:

Dr. Atta ur Rehman

Assistant Professor, Department of Oral & Maxillofacial Surgery Khyber College of Dentistry, Peshawar, Pakistan  
Cell: 0345-9355309

E-mail: dratta80@yahoo.com

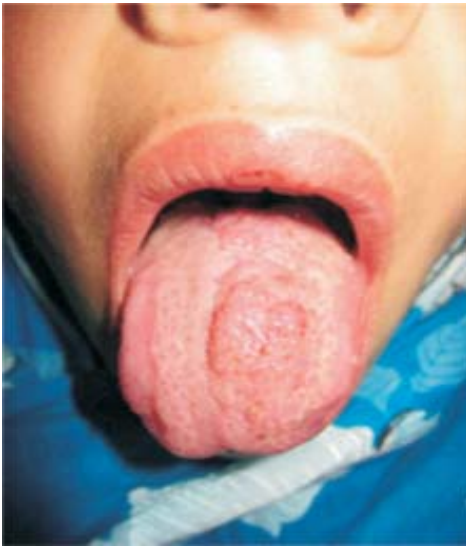


Fig. 1: Angiokeratoma of dorsal surface of tongue.

## DISCUSSION

The first case of angiokeratoma was reported by Mibelli<sup>10</sup> in 1889 on fingers and toes. Fabry<sup>11</sup> described a localized lesion on lower extremity in 1915 and was termed as Angiokeratoma circumscriptum. Solitary angiokeratoma without systemic involvement is rare and majority remains unreported. It occurs predominantly on lower extremities but may also be found in areas like scrotum, vulva, clitoris, and on tongue<sup>12</sup>.

Angiokeratoma of oral cavity can occur as a part of both diffuse and localized forms<sup>3</sup>. It is often associated with some underlying metabolic disorder, however it can be found in localized form. Few cases of angiokeratoma of oral cavity in association with angiokeratoma of scrotum (Fordyce type) have been reported<sup>3</sup> or in association with jejunum<sup>13</sup>.

In this case, two lesions were present on the tongue without underlying metabolic disorder or systemic involvement. According to classification by Ranjanetal, current case is type 1A m (multiple)<sup>9</sup>. Few cases of angiokeratoma occurring on tongue have been reported in pediatric patients on dorsum<sup>14</sup> and ventral surface of tongue<sup>15,16,17</sup>. All the pediatric patients reported were males while the present case was found in 10 year old female. Leung et al<sup>4</sup> reported angiokeratoma of mucosa in an 82 years old man with a history of squamous cell carcinoma of ear and scalp. Two cases of congenital

solitary angiokeratomas of the tongue have been reported<sup>9</sup>.

In adults, the isolated lesions occurred on ventral surface, tip, lateral border of tongue, buccal mucosa and tonsillar pillar. Varshney<sup>18</sup> reported it to be asymptomatic, however it may be associated with bleeding, discomfort and cosmetic concerns. Life threatening bleeding is not a concern, however excessive bleeding after incisional biopsy was reported in one case having deficiency of clotting factor VIII which was an incidental finding<sup>19</sup>. Clinically, bleeding from angiokeratoma lesion can be mistaken for a number of lesions like melanocytic nevus, malignant melanoma, verruca vulgaris, hemangioma, capillary aneurysm or focal epithelial hyperplasia<sup>6</sup>.

Histopathology of Angiokeratoma reveals, ectasia of vascular channels, increased blood filled spaces associated with epithelial hyperplasia and keratosis. Histopathological features of solitary oral angiokeratoma are similar to those arising in skin. In both sites acanthosis and papillomatosis of squamous epithelium can be seen<sup>20</sup>, however the oral lesions show more hyperparakeratosis while the cutaneous lesions show hyperorthokeratosis<sup>5</sup>. Thrombosis of the vessels may occur resembling melanoma<sup>19</sup>. However thrombosis of vessel was not found in present case. In sub epithelial tissue chronic inflammatory infiltrate of lymphocytes and plasma cells were found.

## CONCLUSIONS

- 1) Solitary Angiokeratoma of the tongue, although rare is a distinct clinical entity and should be considered in differential diagnosis of lesions in tongue.
- 2) It can be associated with underlying systemic diseases and may be a source of excessive bleeding.
- 3) Once the diagnosis of angiokeratoma of oral mucosa is known, a thorough examination of skin and mucous membranes be performed having possible association with systemic diseases. Such considerations must be kept in mind during evaluation and treatment of the patient having oral angiokeratoma.

REFERENCES

- 1) Foucar E, Mason WV. Angiokeratoma circumscriptum following damage to underlying vasculature. *Arch Dermatol* 1986; 122(3): 245-6.
- 2) Baccaglini L, Schiffmann R, Brennan MT, Lancaster HE Jr, Kulkarni AB, Brahim JS. Oral and craniofacial findings in Fabry's disease: a report of 13 patients. *Oral Surg Oral Med Oral Pathol Oral Radiol Endod* 2001; 92(4): 415-9.
- 3) Karthikeyan K, Sethuraman G, Thappa DM. Angiokeratoma of the oral cavity and scrotum, *J Dermatol* 2000; 27(2): 131-2.
- 4) Leung CS, Jordan RC. Solitary angiokeratoma of the oral cavity. *Oral Surg Oral Med Oral Pathol Oral Radiol Endod* 1997; 84(1): 51-3.
- 5) Sion-Vardy N, Manor E, Puterman M, Bodner L. Solitary angiokeratoma of the tongue. *Med Oral Patol Oral Cir Bucal* 2008; 13(1): 12-4.
- 6) Schiller PI, Itin PH. Angiokeratomas: an update *Dermatology* 1996; 193(4): 275-82.
- 7) Baccaglini L, Schiffmann R, Brennan MT, Lancaster HE, Jr, Kulkarni AB, Brahim JS. Oral and craniofacial findings in Fabry's disease: A report of 13 patients. *Oral Surg Oral Med Oral Pathol Oral Radiol Endod* 2001; 92: 415-9.
- 8) Ozdemir R, Karaaslan O, Tiftikcioglu YO, Kocer U. Angiokeratoma circumscriptum. *Dermatol Surg* 2004; 30(10): 1364-6.
- 9) Nain M, Agarwal S, Singh GB, Devenga R. Congenital Solitary Angiokeratoma of Tongue: A Rare Case Report. *International Journal of Oral & Maxillofacial Pathology* 2012; 3(2): 72-5.
- 10) Mibelli V. Di una nuova forma di cheratosis, angiokeratoma. *G Ital Mal Vener* 1889; 30: 285-301.
- 11) Fabry J. Ubereinen Fall von angiokeratoma circumscriptum am linken Oberschenkel. *Dermatol Zeitschr* 1915; 22: 1-4.
- 12) Mc Neely TB Angiokeratoma of the Clitoris. *Arch Pathol Lab Med.* 1992; 116(8): 880-1.
- 13) Rappaport I, Shiffman MA. Multiple phlebectasia involving jejunum, oral cavity and scrotum. *JAMA* 1963; 185: 437-40.
- 14) Green JB, Roy S. Angiokeratoma circumscriptum of the dorsal tongue in a child. *Int J Pediatr Dermatol* 2006; 1: 107-9.
- 15) Vijaikumar M, Thappa DM, Karthikeyan K, Jayanthi S. Angiokeratoma circumscriptum of the tongue. *Pediatr Dermatol* 2003; 20: 180-2.
- 16) Kumar MV, Thappa DM, Shanmugam, Ratnakar C. Angiokeratoma circumscriptum of the oral cavity. *Acta Derm Venereol* 1998; 78: 472-4.
- 17) Aggarwal K, Jain VK, Jangra S, Wadhera R. Angiokeratoma Circumscriptum of the Tongue. *Indian Pediatr* 2012; 49: 316-8.
- 18) Varshney S. angiokeratoma circumscriptum of the tongue. *International Journal of Dermatology* 2005; 44: 886-8.
- 19) Flores FA, Sanroman J. Solitary angiokeratoma of the tonsillar pillar of the oral cavity. *Romanian Journal of Morphology and Embryology* 2009; 50(1): 115-7.
- 20) Young WG, Sack JJ, Pihlstrom B, Fish AJ. Histopathology and electron and immunofluorescence microscopy of gingival granulomatosa associated with glossitis and cheilitis in a case of Anderson-Fabry diseases. *Oral surg Oral Med Oral pathol* 1978; 46(4): 540-54.