

PATTERN AND PREVALENCE OF C-SHAPED CANAL IN MANDIBULAR SECOND MOLARS IN PATIENTS ATTENDING SAIDU COLLEGE OF DENTISTRY SWAT, USING CONE BEAM COMPUTED TOMOGRAPHY.

Muhaamad Shahid¹, Rozi Afsar², Umar Nasir³, Shamsul Alam⁴

¹Department of Operative Dentistry, Women Medical and Dental College, Abbottabad

²Department of Oral Biology, Saidu College of Dentistry, Swat

³Department of Oral Biology, KIDS, Kohat

⁴Health department. KP

ABSTRACT

Objectives: To determine the types and prevalence of C-shape canal in lower second molars in patients attending Saidu College of Dentistry Swat, using cone beam computed tomography (CBCT).

Materials and Methods: A total of 200 CBCT images of patients with age range 15 to 60 years, both genders, local residents and clear images having lower second molar area with complete anatomy were included. Images with incomplete root formation, presence of root canal fillings, deep caries, open apices, and root calcification in lower second molars were excluded. Presence and type of C-shape canal in mandibular second molar along with gender and age of the participants were recorded. Classification of C-shaped canal was done according to Fan et al. Descriptive statistics were calculated. Presence and type of C-shaped canal were stratified among genders to see effect modifiers using Fischer exact test.

Results: The mean age of the participants was 32.26 ±8.84 years. The males were 116(58%) and females were 84(42%). The C-shaped canal was present in 16(8.0%) participants. The pattern of C-shaped canal showed that C1 was present in 6(37.5%), both C2 and C3 in 4(25%) and C4 in 2 (12.5%) participants.

Conclusion: In mandibular second molars the occurrence of C-shaped canal is relatively common and the most common type of C-shaped canal is C1 and C2.

Key words: C-shaped canal, mandibular second molar, endodontic treatment, root canal system

INTRODUCTION

Due to anatomical variability in root canal system the endodontic treatment is associated with difficulties.¹ Therefore in-depth knowledge about the normal anatomy of root canal system and common as well as uncommon anatomical variation is very essential for the successful treatment. The quality of endodontic treatment can be greatly improved if the anatomical variations can be taken into consid-

erations.²

A common anatomical variation in root canal system of mandibular molars is C-shaped canal and most frequently found in mandibular second molars.³ This anatomical variation was first documented by Cooke et al in 1979.⁴ In axial plane the orifices of three canal configured into Letter 'C' shape that's why called C-shaped canal.⁵ It is a ribbon like structure just below cemento-enamel junction.⁶ The development of C shaped canal is linked to be due to inability of Hertwig's epithelial root sheath to fuse on buccal or lingual surface of root.⁷

The C-shaped canal was categorized into five types from C1 to C5 by Fan et al.⁸ In C1 the shape

Correspondence:

Rozi Afsar

Assistant professor, Oral Biology, Saidu College of Dentistry, Swat

Cell: +9230058276556

Email: roziafsar15501@gmail.com

of canal is uninterrupted, in C2 canal shape is like semicolon due to discontinuation in outline, in C3 two or three canals are placed separately, in C4 single canal but round or oval in morphology, and in C5 type no lumen of canal is seen.

In Saudi Arabian population frequency of C-shaped canal in lower second molar is 10.6%.⁹ Another investigation in Israel population, on large sample size (n= 1465) found that C-shaped canal prevalence was 4.6%.³

For the successful endodontic treatment, the knowledge of root canal system is very important. To the best of our knowledge no study has been conducted on our population in this region (Swat, Khyber Pakhtunkhwa) on type and prevalence of C-shaped canal in lower second molars using CBCT. There are large variations in prevalence of C-shaped canal across various populations.

This study was aimed to determine the types and prevalence of C-shape canal in mandibular second molars using CBCT.

MATERIALS AND METHODS

This cross-sectional (retrospective) study was conducted at department of Radiology, Saidu College of Dentistry, Swat on available CBCT images of patients. Ethical clearance was obtained from ethical committee (1784/SCD/Swat/ethical). A total of 200 patient’s images were included by non-probability consecutive sampling technique. The inclusion criteria were age range from 15 to 60 years, both genders, and clear CBCT images having lower second molar area with complete anatomy. Images with incomplete root formation, presence of root canal filling, deep caries, open apices, and root calcification in lower second molars were excluded.

CBCT images were taken by Sirona at 70 kilo-volt power, 10 milli-ampere current, scanning time

36 seconds, and exposure time 10 seconds. All images were taken by single radiologist ensuring proper quality of images. Presence and type of C-shape canal were recorded along with gender and age of the participants in mandibular second molars. classification of canal was done on basis of Fan et al.⁸

Statistical analysis for data was performed in SPSS 22. Frequencies and percentages for categorical while mean and Standard deviation (SD) for continuous data were computed. Presence and type of C-shaped canal in mandibular second molars were stratified among genders to see effect modifiers using Fischer exact test. The level of significance under two tailed hypothesis was P less than or equal to 0.05.

RESULT

The mean age of the participants was 32.26 ±8.84 years with range from 17 to 45 years. Details regarding the age and gender are given in (Table: I)

In overall study the C-shaped canal was present in 16 (8.0%) participants. The pattern of C-shaped canal shows that C1 was present in 6 (37.5%), both C2 and C3 in 4 (25%) and C4 in 2 (12.5%) participants. (Fig 1).

The frequency of C-shaped canal was higher in female (n=9, 10.71%) than males (n=7, 6.03%) but this difference was not statistically significant (p=0.347). Similarly, the type of C-shaped canal between genders was not statistically significant (p=0.258). (Table II)

Table-1: Frequency of genders and age groups

Variable	Characteristic	n(%)
Age group (years)	15-25	55 (28)
	26-35	61 (30)
	36-45	84 (42)
Gender	Female	84 (42)
	Male	116 (58)

Table-2: Comparison of frequency and type of C-shaped canal between males and females

Variable	Characteristic	Female (n= 84) n(%)	Male (n= 116) n(%)	p-value*
C-shaped canal	Present	9 (10.71)	7 (6.03)	0.347
Type of C-shaped canal	C1	3 (3.57)	3 (2.59)	0.258
	C2	3 (3.57)	1 (0.86)	
	C3	3 (3.57)	1 (0.86)	
	C4	0 (0.00)	2 (1.72)	
	Not present	75 (89.29)	109 (93.97)	

*Fischer exact test

DISCUSSION

This investigation was conducted for determining the frequency and types of C-shaped canal in mandibular second molars in patients presenting to Saidu College of Dentistry, Swat. Our findings showed that overall, there was 8% prevalence of C-shaped canal and most numerous common patterns was C1 followed by C2 and C3. The frequency of C-shaped canal was little higher in females but was not statistically significant.

We used CBCT in this study. This tool is considered gold standard for detection and classification of C-shaped canal in lower second molar.⁶ Previous studies also used CBCT for studying C-Shaped canal.^{2, 3, 6}

Our findings showed that males were more than females. This can be attributed to more financial independence and more access for males in our population to dental treatment. However, a previous study conducted in Islamabad, Pakistani population on prevalence of C-shaped canal reported that females (n=183) and males (n=177) were almost equal.¹⁰ Another investigation on C-shaped canal prevalence in Korean population reported that females were more than males.¹¹

Current findings revealed that overall C-shaped canal prevalence was 8%. A study was conducted in Saudi Arabian population on 150 cases to determine

the morphology of root canal system in mandibular second molar. They reported the frequency of C-shaped canal in lower second molar is 10.6%.⁹ Another investigation on Israel population on large sample (n= 1465) and reported that overall prevalence of C-shaped canal was 4.6%.³ A CBCT based study was conducted on Korean population on 2508 mandibular second molars and reported that prevalence of C-shaped canal was 36.8%.¹¹ Another study was conducted on Indian population using conventional radiographs on 500 cases reported the overall prevalence of C-shaped canal in lower second molars was 5.2%.¹²

The literature shows a lot of variability for the C-shaped canal prevalence in lower second molars. The difference in results can be attributed to genetic of participants, sample size of the studies, and tool of investigation (clinical, conventional radiograph or CBCT).⁹

Our findings showed that most frequent kind of C-shaped canal was C1 and C2. Similar results were in previous studies.^{3, 10-12}

Limitations connected with this study can be small sample size and distortion of CBCT images. Misalignment of dentition in relation to beam of radiation can create subtle errors resulting in distortion of images and artifacts production.

CONCLUSION

This study concluded that prevalence of C-shaped canal is 8% and most common types are C1 and C2.

REFERENCES

1. Tassoker M, Sener S. Analysis of the root canal configuration and C-shaped canal frequency of mandibular second molars: a cone beam computed tomography study. *Folia Morphol.* 2018;77(4):752-7.
2. Kim H-S, Jung D, Lee H, Han Y-S, Oh S, Sim H-Y. C-shaped root canals of mandibular second molars in a Korean population: a CBCT analysis. *Restorat Dent Endod.* 2018;43(4).
3. Shemesh A, Levin A, Katzenell V, Itzhak JB, Levinson O, Avraham Z, et al. C-shaped canals—prevalence and root canal configuration by cone beam computed tomography evaluation in first and second mandibular molars—a cross-sectional study. *Clin Oral Investigat.* 2017;21(6):2039-44.
4. Cooke HG, Cox FL. C-shaped canal configurations in mandibular molars. *J Am Dent Assoc* 1979; 99:836–39.

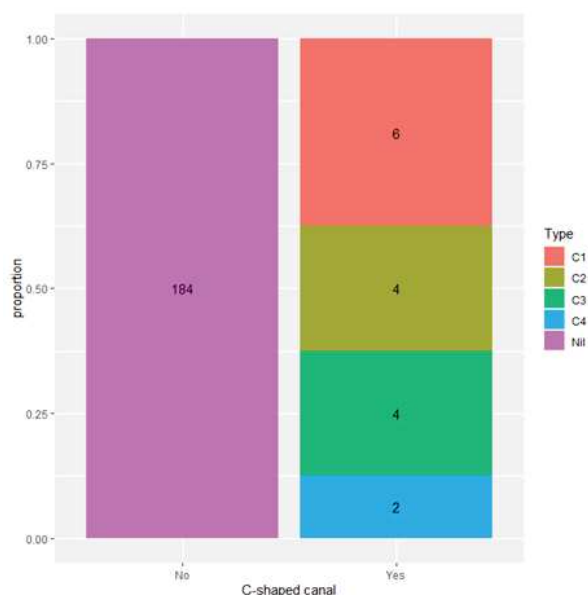


Fig 1: Frequency and type of C-shape canal

5. Mashyakhy M, Chourasia H, Jabali A, Bajawi H, Jamal H, Testarelli L, et al. C-shaped canal configuration in mandibular premolars and molars: Prevalence, correlation, and differences: An In Vivo study using cone-beam computed tomography. *Niger J Clin Pract.* 2020;23(2):232-9.
6. Sherwood AA, Sherwood AI, Setzer FC, Shamili JV, John C, Schwendicke F. A deep learning approach to segment and classify c-shaped canal morphologies in mandibular second molars using cone-beam computed tomography. *J Endod.* 2021;47(12):1907-16.
7. Kaddoura RH, Madarati AA. Management of an over-extruded fragment in a C-shaped root canal configuration: A case report and literature review. *J Taibah Univ Med Sci.* 2020;15(5):431-34.
8. Fan B, Cheung GSP, Fan M, Gutmann JL, Bian Z. C-shaped canal system in mandibular second molars: Part I-Anatomical features. *J Endod* 2004;30:899-903.
9. Al-Fouzan K. C-shaped root canals in mandibular second molars in a Saudi Arabian population. *Int End J.* 2002;35(6):499-504.
10. Ulfat H, Ahmed A, Javed MQ, Hanif F. Mandibular second molars' C-shaped canal frequency in the Pakistani subpopulation: A retrospective cone-beam computed tomography clinical study. *Saudi Endod J.* 2021;11(3):383.
11. Yang SE, Lee TY, Kim KJ. Prevalence and morphology of C-shaped canals: a CBCT analysis in a Korean population. *Scanning.* 2021;2021(21):1-8.
12. Dhawan R, Sharma K, Dahiya S, Kukreja N, Khanna V, Makan K. Incidence of C-Shaped Root Canals in Mandibular Second Molars in North Indian Population: An in-vivo study. *Eur J Molec Clin Med.* 2021;8(2):2029-39.