

BUCCAL BONE THICKNESS IN RETROMOLAR AREA IN RELATION TO BONE GRAFTING PRIOR TO DENTAL IMPLANTS. A CONE BEAM COMPUTED TOMOGRAPHY STUDY

Ali Farooq¹, Armaghan Israr Mirza², Rabia Naseer³, Rafay Mannan Mian⁴,
Tahmasub Faraz Tayyab⁵, Saira Khalid⁶

¹ Oral and Maxillofacial Surgery Department, College of Dentistry Sharif Medical And Dental College Lahore

² Oral And Maxillofacial Surgery Department, King Edward Medical University, Lahore

³ Oral And Maxillofacial Surgery, University College Of Dentistry, University College of Lahore

⁴ Oral And Maxillofacial Surgery, de'Montmorency College of Dentistry Lahore

⁵ University College of Dentistry, University College of Lahore

⁶ Dental Surgeon, Dhq Hospital Kasur

ABSTRACT

Objective: To investigate the buccal bone thickness lateral to Inferior alveolar nerve at mandibular retromolar area using cone beam computed tomography (CBCT) scans.

Materials and Methods: CBCT records of patients attending department of oral and maxillofacial surgery, University College of Dentistry, University College of Lahore from January 2018 till April 2020 were included in the present study. CBCT software was used to generate slices of 10mm in width starting from the cemento-enamel junction (CEJ) on the distal side of the lower second molar in the panoramic view. The sagittal cross section at this point was used to measure the shortest distance from inferior alveolar nerve (IAN) to the outer cortical plate of mandible on both sides of mandible. *t*-test was used to compare the mean bone thickness.

Results: There was no significant difference in mean bone thickness between the right and left side of mandible in both the genders ($P > 0.05$). However, mean bone thickness varied significantly on right ($P = 0.012$) and left side ($P = 0.019$) of mandible between males and females.

Conclusion: Retromolar area is a convenient source of autogenous bone as there is adequate thickness of bone in males and female however, care should be taken in females when retromolar area is chosen as a donor site. The role of CBCT in preoperative planning is crucial in determining the exact dimensions of the buccal bone thickness.

Keywords: dental implant, retromolar, bone grafting, ramus

INTRODUCTION

Dental implants are increasingly being used to rehabilitate patients with missing dentition in aesthetically vital areas¹ as well as completely edentulous

and partially edentulous patients where speech, mastication, smile and swallowing is compromised as a result of tooth loss.² Dental extraction is followed by a physiological process which results in shrinkage of alveolar bone volume, the extent of which depends upon many local systemic factors.³ This can pose significant challenge to dental implant placement when an implant supported prosthesis is planned.⁴ In addition, placing dental implants in such compromised anatomic sites may result in compromised prosthesis.⁵ Bone grafting deficient alveolar ridges

Correspondence:

Dr Ali Farooq

Assistant Professor, Oral and Maxillofacial Surgery, College of Dentistry Sharif Medical And Dental College Lahore, Pakistan.

Email: ali_farooq_82@yahoo.com

Contact: +923214333014

can result in aesthetically pleasing results as dental implants can be placed in ideal position.⁶

Different materials such as autografts, allografts, xenografts and alloplasts are used for bone augmentation procedures⁷ however, autogenous bone grafts are still regarded as “gold standard”.⁸ Intraoral donor sites includes mandibular body and ramus,⁹ symphysis,¹⁰ Coronoid process,¹¹ the anterior wall of maxillary sinus,¹² maxillary tuberosity¹³ and zygomatic bone.¹⁴ Mandibular retromolar area is the most common bone donor site. Exposure of Inferior alveolar nerve (IAN) may occur during the bone harvesting procedure which may result in neurosensory damage¹⁵ therefore, a thorough understanding of its course through the mandible is required to prevent such consequences.¹⁶

The main objective of this study was to investigate the buccal bone thickness lateral to IAN at mandibular retromolar area using available cone beam computed tomography (CBCT) scans of the patients.

MATERIALS AND METHODS

Data was collected from CBCT records of patients attending department of oral and maxillofacial surgery, University College of Dentistry, University College of Lahore from January 2018 till April 2020. A total of 164 CBCT records were analysed and 44 records satisfying the inclusion and exclusion criteria were included in the study. The images were acquired using a CBCT scanner (Planmeca, Finland) and were based on the following parameters: 90KV, 8mA, exposure time of 12 seconds and voxel size of 200 μ m. Images were subjected to a three-dimensional treatment and visualisation and measurement was done using the Romexis Viewer software (Planmeca OY, Finland). Records were excluded from the study if they had mandibular third molars, mandibular fractures, or any pathology in the posterior segments of the mandible. Inclusion criteria included presence of posterior teeth up to second molar on both sides of mandible.

To measure the bone thickness lateral to the IAN in the retromolar area the software was used to generate slices of 10mm in width starting from the cemento-enamel junction (CEJ) on the distal side of the lower second molar in the panoramic view as shown in figure 1. The sagittal cross section at this

point was used to measure the shortest distance from IAN to the outer cortical plate of mandible on both sides of mandible as shown in figure 2.

All data were statistically analysed using SPSS software, version 23 (SPSS Inc.; IL, USA). t- test was used compare the mean bone thickness on the right and left sides of mandible within each gender group and also to compare the mean bone thickness between the two genders. P value of < 0.05 was considered significant.

RESULTS

There was a total of 20 male patients with a mean age of 46.5 \pm 10.5 years and 24 female patients with a mean age of 39.2 \pm 11.2 years. The mean thickness of bone buccal to IAN on right side of mandible in males was 4.4 \pm 1.20mm while on the left side it was 4.7 \pm 1.25 mm (figure 3). The difference between the sides was not statistically significant p=0.41. The buccal bone thickness on the right side in females was 3.5 \pm 1.01mm while on the left side it was 3.9 \pm 1.02mm (figure 4). The difference between the two sides was statistically not significant p=0.20 Table 1.

We found statistically significant difference in the thickness of bone on the right (p=0.012) and left (p=0.019) sides of mandible between males and females as shown in Table 2.

DISCUSSION

Tracing IAN on CBCT is a reliable method to determine its course through the mandible. For the purpose of preoperative treatment planning for any surgical procedure on mandible it should be done in the region where surgery is intended.^{17,18}

Mandibular surgery can be associated with complications associated with neurovascular bundle such as excessive bleeding from damaged inferior alveolar artery and chronic pain of neurogenic origin which can affect the quality of life of the patients.¹⁹ Surgical procedures such as dental implant insertion and bone grafting prior to dental implants can be influenced by anatomic location of IAN within the mandible.¹⁵ Additionally, one must also be familiar with the anatomical variation associated with nerve and mandibular canal.^{17,20} Knowledge of the bone thickness between the IAN and the outer cortical plate of the mandible is prudent for autogenous bone harvest from retromolar area.²¹ Huang et al²² reported that the chances of having neurosensory

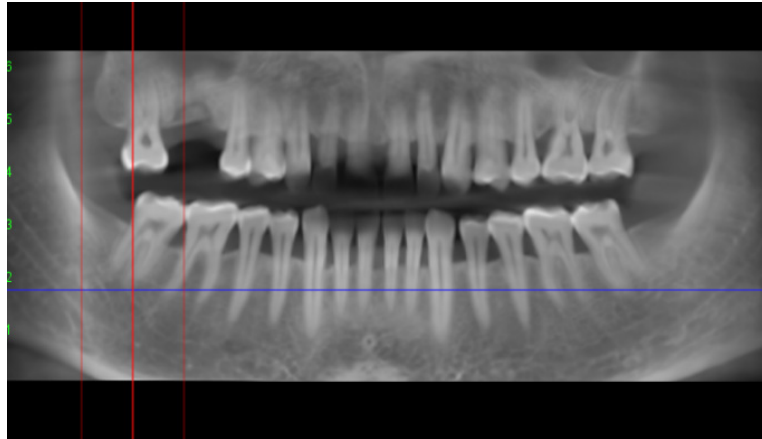


FIG 1: 10mm from CEJ on the distal aspect of second molar

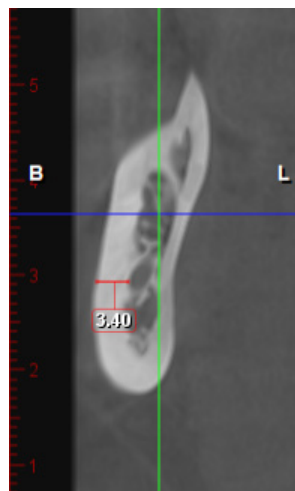


FIG 2: Sagittal view to measure the shortest distance from IAN to outer cortex

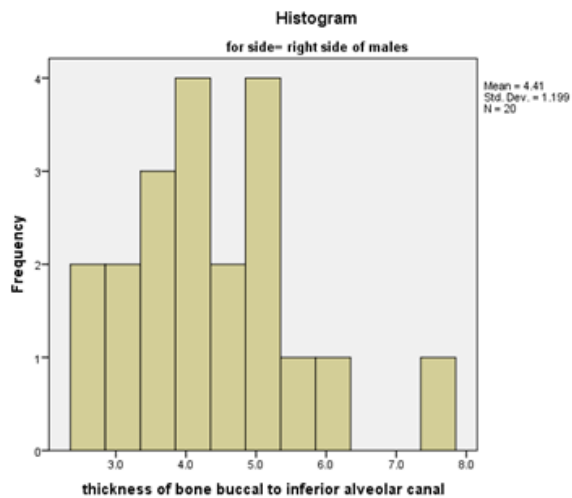


FIG 3: Histograms showing bone thickness on right and left sides of males

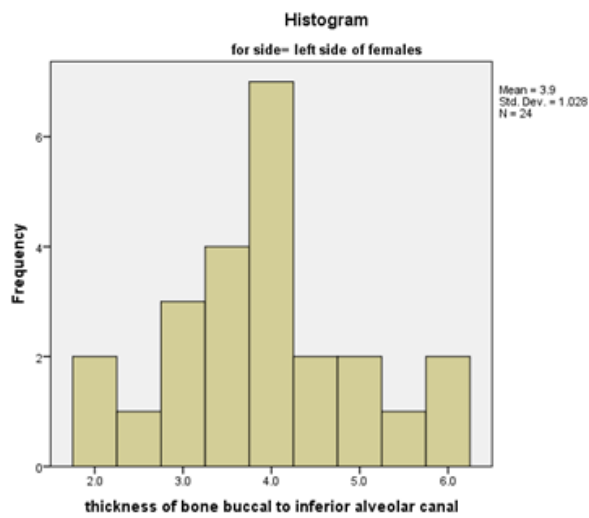
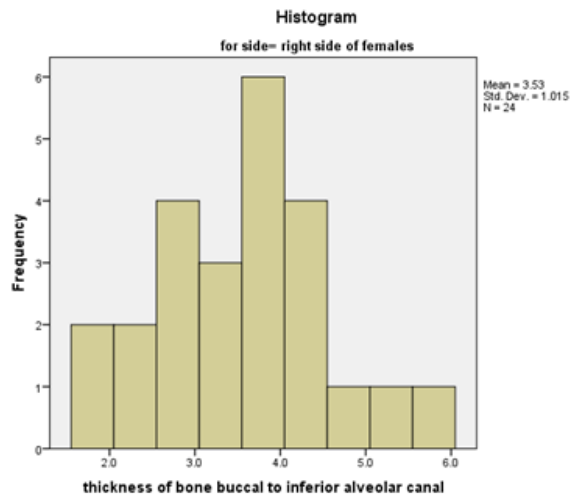
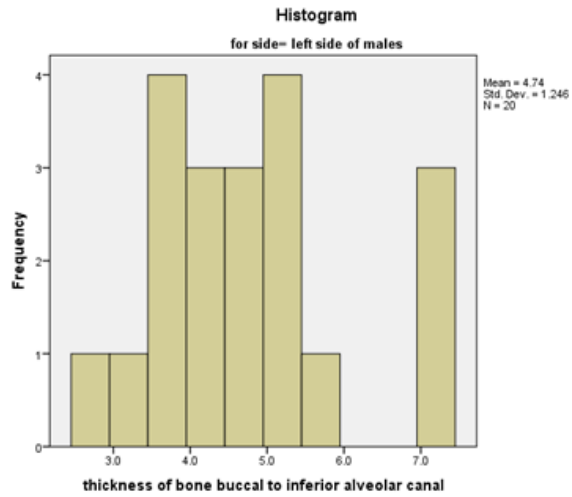


FIG 4: Histograms showing bone thickness on right and left sides of females

disturbances after orthognathic surgery on mandible increases if the buccal cortical dimensions are less. This predisposition has been described previously by Yoshioka et al. in numerous reports.²³⁻²⁵

Reich²⁶ described a mean distance of 2.83mm from the buccal cortical plate of the mandible to the IAN while Misch²⁷ reported a thickness of 4mm from the buccal cortex to the IAN. In the present study, the mean bone thickness on right and left side in males was 4.4±1.20mm and 4.7±1.25 mm while in females on right side it averages 3.5±1.01mm while on the left side it was 3.9± 1.02mm.

The anatomic location of the IAN also varies in buccolingual direction during its course within the canal as it runs through the mandible. In the second molar region the lateral cortical bone thickness is 3.4 mm ± 0.9 mm while in third molar and ramus it varies between 3.5 mm ± 0.7 mm, and 3.0 mm ± 1.2 mm (28). This variation was also confirmed recently by Valdec et al (15) where the researchers reported the buccal bone thickness to be 4mm near the mental foramen, 6mm in the mandibular body and 3mm in the ramus near the mandibular foramen. The mean bone thickness on both sides of mandible did not vary significantly within each gender group in the current study as has been described previously in a recent report.¹⁵ However, the bone thickness on both sides of mandible differed significantly between males and females in our study. These results are partly consistent with those of Zhao et al,²⁹ Deguchi et al,³⁰ and Lim et al³¹ where authors reported thin buccal bone in female but the difference between the genders was not significant. Our results may differ because of our relatively small sample size and in all above mentioned studies measurements were made in dentate regions of mandible while we measured the bone thickness 10mm distal to second molar. On the contrary thick buccal bone in females have been reported by Ono et al.³² Preoperative planning on CBCT also has limitations which should be taken into consideration while planning a surgery on lower jaw.¹⁷ Velázquez et al³³ concluded that on average there is a difference of 1.15mm in buccal bone thickness when measured on radiological scans and on anatomical specimens which should be taken into account while planning on CBCT.

CONCLUSIONS

We conclude that within limitations retromolar

area is a convenient source of autogenous bone as there is adequate thickness of bone in males and female however, care should be taken in females when retromolar area is chosen as a donor site. Furthermore, the results of the study highlight the significance of CBCT in preoperative planning for bone harvest from retromolar area as it provides exact dimension of the cortical bone thickness buccal to IAN.

REFERENCES

1. Smeets R, Stadlinger B, Schwarz F, Beck-Broichsitter B, Jung O, Precht C, et al. Impact of Dental Implant Surface Modifications on Osseointegration. *Biomed Res Int.* 2016;2016:6285620.
2. Tagliareni JM, Clarkson E. Basic concepts and techniques of dental implants. *Dent Clin North Am.* 2015;59(2):255-64.
3. Avila-Ortiz G, Chambrone L, Vignoletti F. Effect of alveolar ridge preservation interventions following tooth extraction: A systematic review and meta-analysis. *J Clin Periodontol.* 2019;46 Suppl 21:195-223.
4. Avila-Ortiz G, Elangovan S, Kramer KW, Blanchette D, Dawson DV. Effect of alveolar ridge preservation after tooth extraction: a systematic review and meta-analysis. *J Dent Res.* 2014;93(10):950-8.
5. Cabezas-Mojón J, Barona-Dorado C, Gómez-Moreno G, Fernández-Cáliz F, Martínez-González JM. Meta-analytic study of implant survival following sinus augmentation. *Med Oral Patol Oral Cir Bucal.* 2012;17(1):e135-9.
6. Andersson L. Patient self-evaluation of intra-oral bone grafting treatment to the maxillary frontal region. *Dent Traumatol.* 2008;24(2):164-9.
7. Milinkovic I, Cordaro L. Are there specific indications for the different alveolar bone augmentation procedures for implant placement? A systematic review. *Int J Oral Maxillofac Surg.* 2014;43(5):606-25.
8. Altıparmak N, Akdeniz SS, Diker N, Bayram B, Uckan S. Comparison of Success Rate of Dental Implants Placed in Autogenous Bone Graft Regenerated Areas and Pristine Bone. *J Craniofac Surg.* 2020.
9. Carlsen A, Gorst-Rasmussen A, Jensen T. Donor site morbidity associated with autogenous bone harvesting from the ascending mandibular ramus. *Implant Dent.* 2013;22(5):503-6.
10. Al-Ani O, Nambiar P, Ha KO, Ngeow WC. Safe zone for bone harvesting from the interforaminal region of the mandible. *Clin Oral Implants Res.* 2013;24 Suppl A100:115-21.
11. Sabhlok S, Waknis PP, Gadre KS. Applications of coronoid process as a bone graft in maxillofacial surgery.

- J Craniofac Surg. 2014;25(2):577-80.
12. Anitua E, Alkhraisat MH, Miguel-Sánchez A, Orive G. Surgical correction of horizontal bone defect using the lateral maxillary wall: outcomes of a retrospective study. *J Oral Maxillofac Surg.* 2014;72(4):683-93.
 13. Khojasteh A, Nazeman P, Tolstunov L. Tuberosity-alveolar block as a donor site for localised augmentation of the maxilla: a retrospective clinical study. *Br J Oral Maxillofac Surg.* 2016;54(8):950-5.
 14. Sakkas A, Schramm A, Karsten W, Gellrich NC, Wilde F. A clinical study of the outcomes and complications associated with zygomatic buttress block bone graft for limited preimplant augmentation procedures. *J Cranio-maxillofac Surg.* 2016;44(3):249-56.
 15. Valdec S, Borm JM, Casparis S, Damerau G, Locher M, Stadlinger B. Vestibular bone thickness of the mandible in relation to the mandibular canal—a retrospective CBCT-based study. *Int J Implant Dent.* 2019;5(1):37.
 16. Misch CM. Use of the mandibular ramus as a donor site for onlay bone grafting. *J Oral Implantol.* 2000;26(1):42-9.
 17. Agbaje JO, de Castele EV, Salem AS, Anumendem D, Lambrechts I, Politis C. Tracking of the inferior alveolar nerve: its implication in surgical planning. *Clin Oral Investig.* 2017;21(7):2213-20.
 18. Kainmueller D, Lamecker H, Seim H, Zinser M, Zachow S. Automatic extraction of mandibular nerve and bone from cone-beam CT data. *Med Image Comput Comput Assist Interv.* 2009;12(Pt 2):76-83.
 19. Politis C, Lambrechts I, Agbaje JO. Neuropathic pain after orthognathic surgery. *Oral Surg Oral Med Oral Pathol Oral Radiol.* 2014;117(2):e102-7.
 20. Zahedi S, Mostafavi M, Lotfirikan N. Anatomic Study of Mandibular Posterior Teeth Using Cone-beam Computed Tomography for Endodontic Surgery. *J Endod.* 2018;44(5):738-43.
 21. Phillips DJ, Swenson DT, Johnson TM. Buccal bone thickness adjacent to virtual dental implants following guided bone regeneration. *J Periodontol.* 2019;90(6):595-607.
 22. Huang CS, Syu JJ, Ko EW, Chen YR. Quantitative evaluation of cortical bone thickness in mandibular prognathic patients with neurosensory disturbance after bilateral sagittal split osteotomy. *J Oral Maxillofac Surg.* 2013;71(12):2153.e1-10.
 23. Yoshioka I, Tanaka T, Khanal A, Habu M, Kito S, Kodama M, et al. Relationship between inferior alveolar nerve canal position at mandibular second molar in patients with prognathism and possible occurrence of neurosensory disturbance after sagittal split ramus osteotomy. *J Oral Maxillofac Surg.* 2010;68(12):3022-7.
 24. Yoshioka I, Tanaka T, Khanal A, Habu M, Kito S, Kodama M, et al. Correlation of mandibular bone quality with neurosensory disturbance after sagittal split ramus osteotomy. *Br J Oral Maxillofac Surg.* 2011;49(7):552-6.
 25. Yoshioka I, Tanaka T, Habu M, Oda M, Kodama M, Kito S, et al. Effect of bone quality and position of the inferior alveolar nerve canal in continuous, long-term, neurosensory disturbance after sagittal split ramus osteotomy. *J Cranio-maxillofac Surg.* 2012;40(6):e178-83.
 26. Reich RH. [Anatomical studies on the course of the mandibular canal]. *Dtsch Zahnarztl Z.* 1980;35(11):972-5.
 27. Misch CM. Comparison of intraoral donor sites for onlay grafting prior to implant placement. *Int J Oral Maxillofac Implants.* 1997;12(6):767-76.
 28. Aalam AA, Nowzari H. Mandibular cortical bone grafts part 1: anatomy, healing process, and influencing factors. *Compend Contin Educ Dent.* 2007;28(4):206-12; quiz 13.
 29. Zhao H, Gu XM, Liu HC, Wang ZW, Xun CL. Measurement of cortical bone thickness in adults by cone-beam computerized tomography for orthodontic miniscrews placement. *J Huazhong Univ Sci Technolog Med Sci.* 2013;33(2):303-8.
 30. Deguchi T, Nasu M, Murakami K, Yabuuchi T, Kamio-ka H, Takano-Yamamoto T. Quantitative evaluation of cortical bone thickness with computed tomographic scanning for orthodontic implants. *Am J Orthod Dentofacial Orthop.* 2006;129(6):721.e7-12.
 31. Lim JE, Lim WH, Chun YS. Quantitative evaluation of cortical bone thickness and root proximity at maxillary interradicular sites for orthodontic mini-implant placement. *Clin Anat.* 2008;21(6):486-91.
 32. Ono A, Motoyoshi M, Shimizu N. Cortical bone thickness in the buccal posterior region for orthodontic mini-implants. *Int J Oral Maxillofac Surg.* 2008;37(4):334-40.
 33. Azcárate-Velázquez F, Bertos-Quilez J, Marmesat-Guerrero F, Núñez-Arcos P, Hernández-Alfaro F, Ferrés-Padrós E, et al. Fiabilidad del uso de la tomografía computarizada de haz cónico en la localización y medida del conducto mandibular en la planificación de técnicas quirúrgicas en el cuerpo mandibular. *Rev Esp Cir Oral Maxilofac.* 2015;37:182–187