

PATTERN OF COVID-19 ASSOCIATED MAXILLARY MUCORMYCOTIC OSTEOMYELITIS

Ahmad Khan¹, Atta Ur Rehman², Sertaj Khan¹, Muhammad Sohail¹,
Muhammad Tariq Khan³, Syed Ayaz Ali¹, Syed Asad Shah¹, Muhammad Hussain⁴

¹ Department of Oral and Maxillofacial Surgery, Bacha Khan Medical College/ Mardan Medical Complex Mardan.

² Department of Oral and Maxillofacial Surgery, Khyber College of Dentistry Peshawar.

³ Department of Oral and Maxillofacial Surgery, Saidu Medical College, Swat.

⁴ Department of Surgery, Bacha Khan Medical College/ Mardan Medical Complex Mardan.

ABSTRACT

Objective: To evaluate the occurrence of mucormycotic osteomyelitis in our area regarding age, gender, side of involvement of maxilla and any associated systemic diseases and treatment modality adopted in our centre.

Materials and Methods: Data of 21 patients presented with the features of mucormycotic osteomyelitis at Oral and Maxillofacial Surgery Unit, Bacha Khan Medical College Mardan from June 2020 to May 2021 was recorded. Non probability, convenience sampling technique was used. History, clinical, radiographic and histopathological examination was performed for diagnosis. Treatment included antibiotic, antifungal and serial debridement. Defects were closed by local flaps and by prosthetic obturator. Data regarding the age, gender, side of involvement of maxilla and any associated systemic diseases and treatment modality were evaluated and analyzed by Spss Version 22.

Results: The mean age was 58.90 ± 21.5 years, with an age range of 35-78 years. Age group 61-70 years were most commonly affected (38.1%). The ratio of male and female was 2.5:1. Left maxilla (62.1%) was commonly affected in both male and female. Diabetes as associated disease (52%) dominated followed by diabetes and hypertension (33.3%). One case (4.9%) has no associated disease. All cases were treated by antibiotic and antifungal therapy and serial debridement. Defects were closed in 14 cases (66.6%) by local flaps and 7 cases (33.4%) by prosthetic obturators

Conclusion: COVID-19 is associated with significant incidence of secondary opportunistic infections due to immune dysregulation. The treatment of COVID-19 itself pre-disposes the patients to development of fungal diseases.

Keywords: Mucormycosis, Osteomyelitis, COVID-19, Associated Diseases

INTRODUCTION

Corona virus disease 2019 (COVID-19) outbreak has severely affected the field of medical science all over the world. This novel strain of severe acute respiratory syndrome coronavirus 2 (SARSCoV-2) causes a wide range of disease patterns and associ-

ated morbidities, putting additional challenges for medical science.¹

More severe disease is caused by systemic inflammation and coagulopathy damaging the blood vessels leading to cardiac, renal and hepatic injuries. This coagulopathy is due to complement mediated thrombotic microangiopathies. This causes endothelial damage and microvascular thrombosis.²

Maxilla forms the middle part of the face and plays an important role mastication, speech and esthetics. There is high blood supply to maxilla as

Correspondence:

Dr. Atta-Ur- Rehman

Associate Professor Oral & Maxillofacial Surgery Khyber College of Dentistry Peshawar, Pakistan.

Email: dratta80@yahoo.com

Contact: :+923459355309

compared to mandible. Necrosis of maxilla is not common, but may occur in some cases due to bacterial, viral infections or fungal infections.³

Mucormycosis is a life threatening condition mainly affecting the immunocompromized patients with diabetic ketoacidosis, neutropenia, organ transplant, steroid use and high serum iron levels.⁴

Osteomyelitis is an inflammatory condition involving the bone. It usually initiates from the medullary cavity, rapidly involving the Haversian systems, and extending to the periosteum of the area.^{1,4} The involvement of fungus in the bone marrow renders the fungal organisms' growth, affecting the endothelial lining of vessels causing vascular insufficiency eventually leading to necrosis of the bone developing into fungal osteomyelitis.⁴

Globally, diabetes mellitus (DM) is one of the major causes of morbidity due to the development of an immunocompromised state in patients. It causes hyperglycemia, affecting the defense mechanism of the body. The presence of fungus in the bone marrow promotes fungal growth by damaging the endothelial lining of vessels, resulting in vascular insufficiency and finally bone necrosis, leading to fungal osteomyelitis.^{5,6}

In the backdrop of this COVID-19 disease, there has been a significant rise in the incidence of invasive fungal infections of the maxillofacial region i.e. mucormycosis.⁷ COVID-19 patients are predisposed to developing fungal infections during the course of disease and also in later stages, especially immunocompromised, due to a decrease of CD4 + T cells and CD8 +T cells causing immune suppression.⁸

Early diagnosis and treatment is key to improving outcome for patients with COVID-19-associated mucormycotic osteomyelitis. Diagnosis of fungal infections is based on direct microscopy with KOH mounted slides and confirmatory diagnosis is based on definitive histological evidence of tissue invasion and culture supplemented with CT and MRI.^{8,9} Treatment modality includes control of the underlying risk factors, antifungal therapy, surgical debridement, supportive therapy, and surgical or prosthetic rehabilitation to restore the premorbid function of the patients.

We presume that the use of steroid, immunocompromised status and thrombotic microangiopathies

in COVID-19 provides an ideal environment for mucormycotic osteomyelitis in maxilla. There may be cause and effect relationship among these factors developing this disease.

MATERIALS AND METHODS

The present descriptive study had been carried out on 21 consecutive patients of both gender and any age group presenting with the features of mucormycotic osteomyelitis of maxilla to Oral and Maxillofacial Surgery Unit, Bacha Khan Medical College Mardan from June 2020 to May 2021. Non probability, convenience sampling technique was used. Approval of study was taken from ethical committee of the hospital. With the consent of the patients, a detailed history was taken and thorough clinical examination was carried out. Routine investigations, orthopantomogram (OPG) and CT were performed for every patient supplemented by MRI when necessary. Cases already treated were excluded from the study. The diagnosis, established, was based on history, clinical, radiographic and histopathological examination. Treatment included antibiotic, antifungal and serial debridement. Defects were closed by local flaps and by prosthetic obturator. The data concerning the study was obtained on preformed proforma and evaluated and analyzed by applying descriptive statistics.

RESULTS

Mean age was 58.90 ± 21.5 years, with an age range of 35-78 years. Age group 61-70 years were most commonly affected (38.1%) followed by age group 51-60 years (28.6%) (Table 1). The ratio of male and female was 2.5:1 (Fig 1). Left maxilla (62.1%) was commonly affected in both male and female (Table 2). Diabetes as associated disease (52%) dominated followed by diabetes and hypertension (33.3%). One case (4.9%) has no associated disease (Table 3). All cases were treated by antibiotic and antifungal therapy and serial debridement. Defects were closed in 14 cases (66.6%) by local flaps and 7 cases (33.4%) by prosthetic obturators.

DISCUSSION

Mucormycosis is an uncommon but lethal fungal infection caused by the family of Mucoraceae, which belongs to the class of Phygomycetes or Zygomycetes.¹⁰ This fungus usually present as a commensal of the nasal mucosa and in state of im-

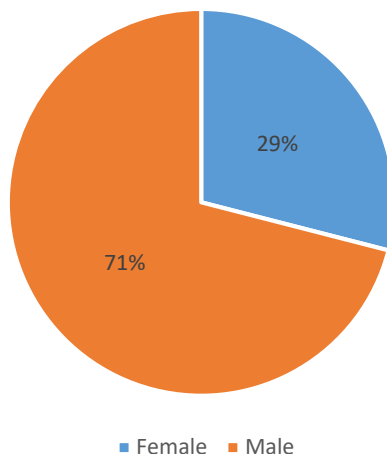


FIG 1: GENDER DISTRIBUTION OF PATIENTS

TABLE 1: Age Distribution of Patients

Age group in years	No	Percentage
31-40	1	4.8
41-50	4	19
51-60	6	28.6
61-70	8	38.1
71-80	2	9.5
Total	21	100

TABLE 2: Distribution According to Gender and Side of Involvement of Maxilla

Gender	Right Maxilla		Left Maxilla		Bilateral Maxilla		Total	
	n	%	n	%	n	%	n	%
Male	5	23.5	10	47.5	0	0	15	71
Female	2	9.5	3	14.6	1	4.9	6	29
Total	7	33	13	62.1	1	4.9	21	100

TABLE 3: Distribution According to Associated Systemic Diseases and Side of Involvement of Maxilla

Associated Systemic Diseases	Right Maxilla		Left Maxilla		Bilateral Maxilla		Total	
	n	%	n	%	n	%	n	%
Diabetes Only	4	19	7	33.3	0	0	11	52
Diabetes + Hypertension	3	14	4	19	0	0	7	33.3
Diabetes + Hepatitis C	0	0	1	4.9	0	0	1	4.9
Hepatitis Only	0	0	0	0	1	4.9	1	4.9
Non Diabetes	0	0	1	4.9	0	0	1	4.9
Total	07	33	13	62.1	1	4.9	21	100

munosuppression like diabetes, ketoacidosis, solid organ transplant, severe burns, etc. can germinate in the nasal cavity and paranasal sinuses to invade the palate, orbits and brain, often leading to death.^{11,12}

Infected lung epithelial cells in patients with COVID-19 produce IL-8 and IL-6. Massive inflammatory cells infiltrate occurs due to lymphopenia. Endothelial cells injury occurs in COVID-19

patients, favoring microvascular permeability and microbial infection. Secondary bacterial and fungal infection developed in COVID-19 patients. Some study suggested that fungal infection occurs 5% COVID-19 patients.¹³

Uncontrolled diabetes makes the patient immunocompromised due to the effects of hyperglycemic state and dysfunction immune system by affecting the neutrophils, antioxidants system and humoral immunity.¹⁴ The growth and invasion of fungal spores is encouraged by high level of glucose, ketone bodies, iron level and low PH. Rhizoferrin generated by fungal hyphae creates iron-rhizoferrin complexes, which are essential for the growth, development, and multiplication of fungal spores.¹⁵

Vegetative form of fungus invades the vessels forming thrombus, leading to ischemic infarcts and necrosis. The long-term use of glucocorticoids has also shown to contribute to mucormycosis in patients by suppressing the immunity making patients liable for opportunistic infections.¹⁶

Osteomyelitis of the facial bone is rare. Involvement of the maxillary bone is uncommon as compared to mandible. Fungal osteomyelitis has reported sporadically all around the world. Several factors are involved in the development of osteomyelitis such as trauma, bacterial and fungal infection and diseases which compromise the host defense system like diabetes, anemia, malignancies, radiation, chemotherapy and malnutrition.¹⁷

In this study the male to female ratio is 2.5:1, which indicates that fungal osteomyelitis associated with COVID-19 is more common in male population as compared to female. Similar reports have also been reported by Moorthy A et al.¹⁸

In this study the most commonly affected age group is 61-70 years. The study of Moorthy et al¹⁸ reported that males above 40 years are most commonly affected in mucormycotic osteomyelitis in COVID-19 patients. This study also stated that fungal osteomyelitis involved the maxilla more common than mandible in COVID-19 patients. The reports of this study coincide with the present study.

As reported in previous studies,^{18,19} there is a strong correlation of mucormycosis and uncontrolled diabetes in Non COVID-19 patients. Diabetes has also been identified as an independent variable as-

sociated with severity of COVID-19 infection and hospitalization.

A study of by Urs et al¹⁹ reported 5 cases of fungal osteomyelitis. Three cases involved the maxilla and 2 cases have history of uncontrolled diabetes. Niranjana et al²⁰, in their study reported 52% fungal osteomyelitis of the jaws associated with diabetes mellitus, occurred in 52% whereas 48% belonged to other causes. They also reported fungal osteomyelitis more in male and above 40 years of age. Maxilla was commonly affected in patients with diabetes mellitus.

It is presumed that the recent surge in the maxillary osteomyelitis in post COVID-19 patients is attributed to many factors. The immune dysregulation in COVID-19 patients in form of reduction of T lymphocytes, CD4+ T and CD8+ T cells increases the chances for opportunistic infections. There is a stark resemblance in the pathophysiology of COVID-19 and mucormycosis in form of angioinvasion and endothelial damage. Finally, steroid is rampantly used for the treatment of COVID-19 infection in very patient. The immune suppression caused by steroid use makes the patient susceptible to various opportunistic infections.¹⁸

Diabetes mellitus and host response to SARS-CoV-2 have similarities in pathophysiology that may cause favorable situation for the growth and development and multiplication of fungal spores resulting in osteomyelitis of maxilla. COVID-19 infection badly affects the glycemic control, and the use of steroid further exacerbates hyperglycemia.²¹

Diabetes in all patients is not a risk factor for osteomyelitis, other immunocompromised states also makes the patients susceptible like chronic hepatitis C and anemia, as evident from the result of the present study. All the patients in present study are COVID-19 positive and 85.3 percent has diabetes and has used the steroid for COVID-19.

Serial surgical debridement, systemic antifungal, antibiotics, closure of the defects, managing the underlying medical illness is pre-requisites for better prognosis.

One non-diabetic young immunocompetent patient in our study developed osteomyelitis of left maxilla. This makes the causal effect relationship between COVID-19 and mucormycosis more complicated as there is paucity of such cases in literature.

Adequate documentation and evidence based studies are required for understanding the mechanism and management of this disease. More studies from other centers are required to establish a clinical protocols for the disease.

CONCLUSIONS

COVID-19 is associated with significant incidence of secondary opportunistic infections due to immune dysregulation. The treatment of COVID-19 itself pre-disposes the patients to development of fungal diseases. The causal effect relationship among COVID-19, steroid use and immunocompromised states is still debatable. Early diagnosis and timely management reduces the morbidity and mortality. More studies are required to establish a clinical protocols for the management of mucormycotic osteomyelitis.

REFERENCES

1. Verma DK, Bali RK. COVID-19 and mucormycosis of the craniofacial skeleton: causal, contributory or coincidental? *J Maxillofac Oral Surg* 2021; 20(2):165–6.
2. Gavriilaki E, Touloumenidou T, Sakellari I, Batsis I, Mallouri D, Psomopoulos F, et al.. Pretransplant genetic susceptibility: clinical relevance in transplant-associated thrombotic microangiopathy. *Thromb Haemost* 2020; 120:638–46.
3. Urs AB, Singh H, Mohanty S, Sharma P. Fungal osteomyelitis of maxillofacial bones: Rare presentation. *J Oral Maxillofac Pathol* 2016; 20:546-10.
4. Sargin F, Akbulut M, Karaduman S, Sungurtekin H. Severe rhinocerebral mucormycosis case developed after COVID 19. *J Bacteriol Parasitol* 2021; 12: 386-8.
5. Jeong W, Keighley C, Wolfe R, Lee WL, Slavin MA, Kong DCM, et al. The epidemiology and clinical manifestations of mucormycosis: a systematic review and meta-analysis of case reports. *Clin Microbiol Infect*. 2019;25(1):26-34.
6. Garde J., Bhagwat H., Vadane A., Gaikwad S. Invasive mucormycosis [zygomycosis] and osteomyelitis affecting maxilla: A rare case report. *Int Dent J Student's Res* 2018;6(3):66-7.
7. Peman J, Gaitan AR, Vidal CG, Salavert M, Ramirez P, Puchades F, Hita MG, Izquierdo AA, Quindo G (2020) Fungal co-infection in COVID-19 patients: should we be concerned? *Rev Iberoam Micol* 37(2):41–46.
8. Bitar D, Lortholary O, Le Strat Y, Nicolau J, Coignard B, Tattevin P. Population-based analysis of invasive fungal infections, France, 2001–2010. *Emerg Infect Dis*. 2014;20 (7):1149–55.
9. Cornely OA, Alastruey-Izquierdo A, Arenz D, Chen SCA, Dannaoui E, Hochhegger B et al. Global guideline for the diagnosis and management of mucormycosis: an initiative of the European Confederation of Medical Mycology in cooperation with the Mycoses Study Group Education and Research Consortium. *Lancet Infect Dis* 2019; 19(12):405–21.
10. Eucker J, Sezer O, Graf B, Possinger K. Mucormycoses. *Mycoses* 2001;44 (7):253-260.
11. Srivastava A, Mohapatra M, Mahapatra A. Maxillary fungal osteomyelitis: a review of literature and Report of a rare case. *Ann Maxillofac Surg* 2019; 9(1): 168–73.
12. Jeong W, Keighley C, Wolfe R, Lee WL, Slavin MA, Kong DCM, et al. The epidemiology and clinical manifestations of mucormycosis: a systematic review and meta-analysis of case reports. *Clin Microbiol Infect*. 2019; 25(1):26-34.
13. Song G, Liang G, Liu W. Fungal co-infections associated with global COVID-19 pandemic: a clinical and diagnostic perspective from China. *Mycopathologia* 2020; 185(4):599–606.
14. Akash MSH, Rehman K, Fiayyaz F, Sabir S, Khurshid M (2020) Diabetes-associated infections: development of antimicrobial resistance and possible treatment strategies. *Arch Microbiol [Internet]* 202(5):953–65.
15. Krishna DS, Raj H, Kurup P, Juneja M. Maxillofacial infections in Covid-19 era- actuality or the unforeseen: 2 case reports. *Indian J Otolaryngol Head Neck Surg*. 2021; 17: 1–4.
16. Gonzalez BDG, Garaa R, Gil F et al (2012) Mucormycosis of head and neck Report of five cases with different presentations. *J Cranio Maxillo Facial Surg* 40:584–591
17. H. M. Kremers, M. E. Nwojo, J. E. Ransom, C. M. WoodWentz, L. J. Melton III, and P. M. Huddleston III, “Trends in the epidemiology of osteomyelitis,” *J Bone Joint Surg* 2015; 97(10):837–45.
18. Moorthy A, Gaikwad R, Krishna S, Hegde R, Tripathi KK, Kale PG et al. SARS-CoV-2 uncontrolled diabetes and corticosteroids—an unholy Trinity in invasive fungal infections of the maxillofacial region? a retrospective, multi-centric analysis. *J Maxillofac Oral Surg* 2021; 6: 1-8.
19. Urs H. Singh S. Mohanty, Sharma P. Fungal osteomyelitis of maxillofacial bones: rare presentation. *J Oral Maxillofac Pathol* 2016;20 (3):546.
20. Niranjana KC, Sarathy N, Alrani D, Hallekeri K. Prevalence of fungal osteomyelitis of the jaws associated with diabetes mellitus in North Indian population: a retrospective study. *Int J Cur Res* 2016; 8 (3):2770-10.
21. Unnikrishnan R, Misra A. Infections and diabetes: risks and mitigation with reference to India. *Diab Metabol Syndr Clin Res Rev* 2020; 14:1889–94.